

SURGICAL PATHOLOGY

**STUDENT BOOK SENIOR 6
ASSOCIATE NURSING PROGRAM**

First Edition

© 2024 Rwanda Basic Education Board

All rights reserved.

This book is the property of Government of Rwanda

Credit should be given to REB when the source of this book is quoted.

FOREWORD

Dear Student,

The Rwanda Basic Education Board is pleased to introduce this textbook of Surgical Pathology of the Associate Nursing Program. This resource is crafted to support competence-based teaching and learning, ensuring a uniform approach to mastering the Surgical Pathology. Our educational philosophy is designed to help you realize your full potential at each level of your education, equipping you to integrate effectively into society and seize career opportunities.

The Rwandan government emphasizes the alignment of educational materials with the syllabus to enhance your learning experience. Instructional materials, activities, and engagement play a crucial role in shaping how well you learn. This textbook focuses on activities that promote idea development and discovery, whether done individually or in groups.

In a competence-based curriculum, learning is an active process where knowledge, skills, and attitude and values are developed through practical activities and real-life scenarios. To fully benefit from this textbook, you should:

- Engage in activities and laboratory experiments to build your skills.
- Share information through presentations, discussions, and collaborative work.
- Take ownership of your learning and draw insights from your activities.

I extend my gratitude to all those who contributed to the creation of this book, including the Ministry of Health, University of Rwanda, and other institutions. Special thanks go to the dedicated faculty members, nurses, midwives, teachers, illustrators, and designers who worked diligently on this project.

Dr. MBARUSHIMANA Nelson
Director General, REB



ACKNOWLEDGEMENTS

I would like to express my deep gratitude to everyone who contributed to the development of this student book. The project would not have succeeded without the support of numerous stakeholders. I extend special thanks to the Ministry of Health for leading the development process. My appreciation also goes to the Health Workforce development staff/MoH, REB staff, University of Rwanda, College of Medicine and Health Sciences, Staff from Health Private training institutions, Teaching hospitals, Level Two Teaching hospitals, district hospitals, National Council of Nurses and Midwives (NCNM) and Secondary schools having Associate Nursing program. Additional thanks are due to the Ministry of Health, the Ministry of Education, and the Clinton Health Access Initiative (CHAI) for their financial support.



Ms. MURUNGI Joan

Head of Curriculum, Teaching, and Learning Resources Department / REB

Table of Contents

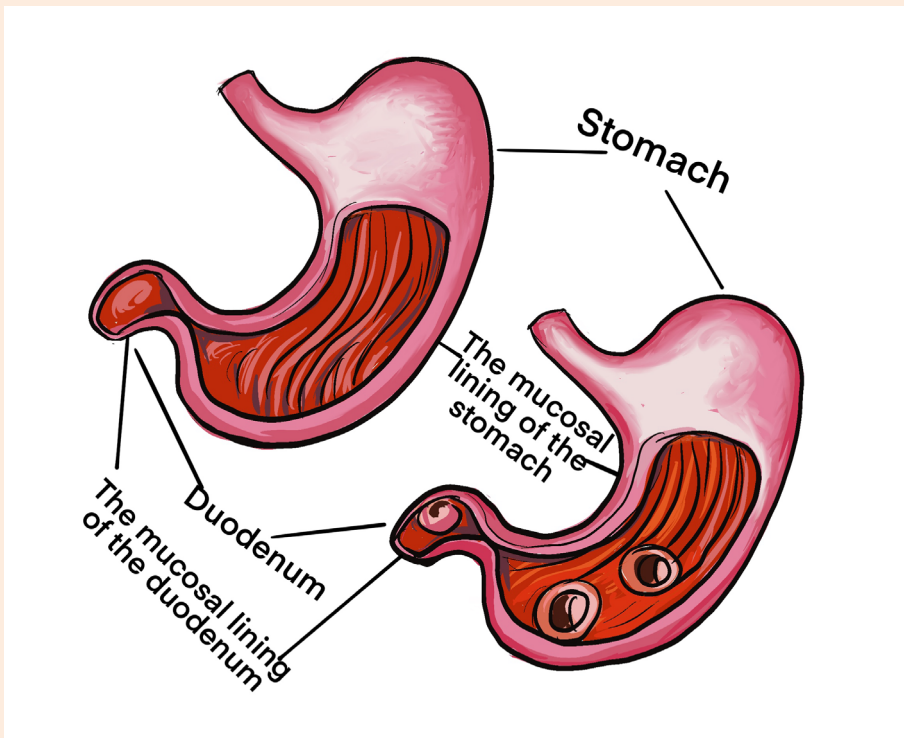
FOREWORD	iii
ACKNOWLEDGEMENTS	iv
UNIT 1: GASTRODUODENAL ULCERS	1
1.1. Description of gastroduodenal ulcers	2
1.2. The management of gastroduodenal ulcers	7
UNIT 2: APPENDICITIS	10
2.1. Description of appendicitis	11
2.2. The management of appendicitis	14
UNIT 3: INTESTINAL OBSTRUCTION	18
3.1. Description of intestinal obstruction	19
3.2. The management of intestinal obstruction	22
UNIT 4: HERNIAS	25
4.1. Abdominal hernias	26
4.2. Hiatal hernia	30
UNIT 5: HEMORRHOIDS	35
5.1. Description of Hemorrhoids	35
5.2. The management of Hemorrhoids	37
UNIT 6: BALANITIS AND BALANOPOSTHITIS	40
6.1. Description of Balanitis and Balanoposthitis	41
UNIT 7: PHIMOSIS AND PARAPHIMOSIS	46
7.1. Description of Phimosis and Paraphimosis	47
UNIT 8: HYDROCELE AND TESTICULAR TORSION	55
8.1. Description of hydrocele	56
8.2. Description of Testicular torsion	61
REFERENCES	66

Key Unit competence

Take appropriate decision on Gastro Duodenal Ulcers conditions.

Introductory activity 1.0

The image A and B illustrate the structures of stomach and duodenum. Observe them and respond to the attached questions.



- 1) Is there any difference between the two images (A&B)?
- 2) What explanations can you give to justify the abnormal structure of stomach and duodenum?
- 3) What do you think can cause the modifications that you have observed?
- 4) What are the manifestations of such abnormalities in the human body?
- 5) How can health personnel identify or notice these abnormalities of stomach and duodenum?
- 6) How can these abnormalities be corrected?

1.1. Description of gastroduodenal ulcers

Learning Activity 1.1

S.D is a 47-year-old police officer who lives and works in urban area. Mr. S.D has now been admitted to the hospital where you are allocated.

*In the past history, Mr. SD has had 'heartburn' and abdominal discomfort for years, but he thought it went along with his job. Last year, after becoming weak, light-headed and short of breath, he was found to be anemic. He said that he took omeprazole and ferrous sulfate for 3 months before stopping both, saying he had 'never felt better in his life'.

*On today's initial assessment, S.D is alert and oriented, though very worried about his condition. Skin pale and cold; BP 136/78, P 98; his abdomen is distended and tender with hyperactive bowel sounds; he has active upper GI bleeding as manifested by 200 mL bright red blood obtained on nasogastric tube that has been inserted.

* The medical doctor is now ordering different diagnostic measures and include FBC (Full Blood Count), endoscopy and a biopsy taken from the stomach and duodenum.

*The results of FBC have indicated low Hemoglobin and low hematocrit. Tissue biopsy obtained during endoscopy confirms the presence of H. pylori infection.

Questions related to the case study

- 1) Identify the biography of the patient described in the case study
- 2) What is the medical history of patient described in the case study?
- 3) Describe the signs and symptoms that the patient present and are described in the case study
- 4) What are the aggravating and relieving factors?
- 5) What is the probable diagnostic method of this S.D?

1.1.1. Definition and the Gastroduodenal ulcers

Gastroduodenal ulcers also known as Peptic ulcer (PU) disease is a condition in which painful sores or ulcers develop in the lining of the stomach or the first part of the small intestine (the duodenum).

1.1.2. Causes and pathophysiology of Gastroduodenal ulcers

Studies have revealed two main causes of peptic ulcers (PU): Helicobacter pylori (H. pylori) bacteria and pain-relieving NSAID medications. There are other many factors of Peptic ulcers.

Risk factors for peptic ulcer disease

- H. pylori infection,
- Low socioeconomic status Crowded, unsanitary living conditions
- Unclean food or water
- Advanced age
- History of PUD
- Concurrent use of other drugs such as glucocorticoids or other NSAIDs
- Cigarette smoking
- Family history of PUD

PU disease is characterized by discontinuation in the inner lining of the gastrointestinal (GI) tract because of an increase in the concentration or activity of gastric acid or pepsin. It extends into the muscularis propria layer of the gastric epithelium. Some individuals have more rapid gastric emptying, which, combined with hypersecretion of acid, creates a large amount of acid moving into the duodenum. As a result, peptic ulcers occur more often in the duodenum. The Pathophysiology of gastroduodenal Ulcer is summarized on the figure 1.1.

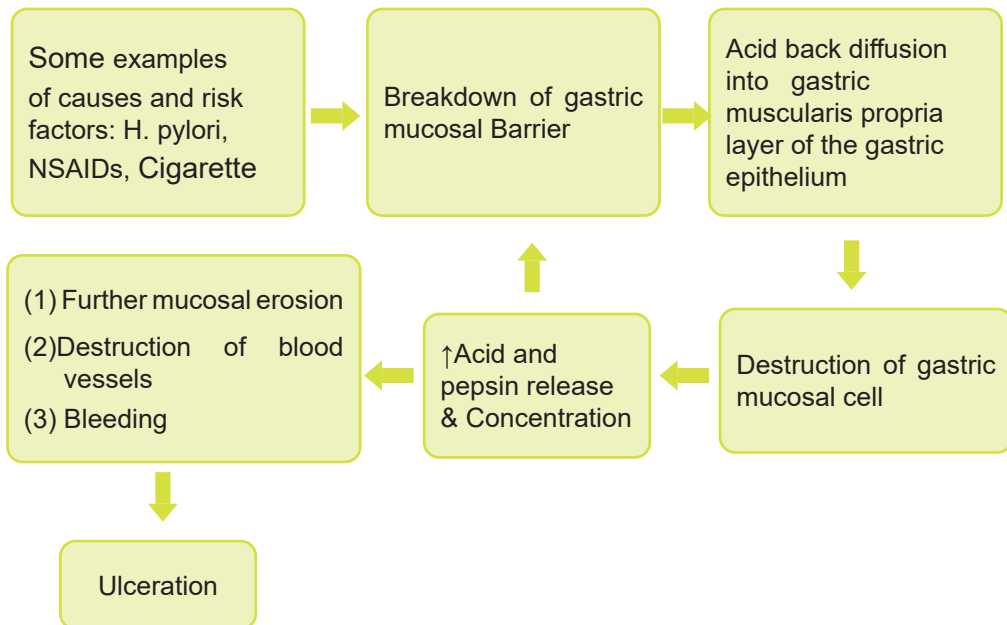


Figure 1.1: Summary of pathophysiology of gastroduodenal ulcers

1.1.3. Signs and symptoms of Gastroduodenal ulcers

Some people with ulcers don't experience any symptoms. But signs of a peptic ulcer can include burning pain in the middle or upper stomach between meals or at night. Pain that temporarily disappears if you eat something or take an antacid, bloating, heartburn, nausea or vomiting.

In severe cases, symptoms can include dark or black stool (due to bleeding), vomiting, weight loss, severe pain in the mid to upper abdomen. Table 1.1 compares the characteristics of duodenal and gastric ulcers.

Table 1.1: COMPARISON OF GASTRIC AND DUODENAL ULCERS

Characteristic	Gastric ulcers	Duodenal ulcers
Lesion	Superficial	Penetrating
Location of lesion	Predominantly in the antrum; also in body and fundus of stomach	First 1–2 cm of duodenum
Gastric Secretion	Normal to decreased	Increased
Incidence	<ul style="list-style-type: none">• Greater in women• Increased with smoking, drug, and alcohol use• Peak age, 50–60 yr.• More common among persons of lower socioeconomic status and in unskilled labourers• Increased with incompetent pyloric sphincter and bile reflux• Increased with stress ulcers after severe burns, head trauma, and major surgery	<ul style="list-style-type: none">• Greater in men, increasing in postmenopausal women• Increased with smoking, drug, and alcohol use• Peak age, 35–45 year• Associated with psychological stress• Associated with other diseases (e.g., chronic obstructive pulmonary disease, pancreatic disease, chronic renal failure)

Clinical manifestations	<ul style="list-style-type: none"> • Burning or gaseous pressure in high left epigastrium and back and upper abdomen • Burning, cramping, pressure-like pain across midepigastrum and upper abdomen; back pain with posterior ulcers • Pain 1–2 hr. after meals; if penetrating ulcer, aggravation of discomfort with food • Occasional nausea and vomiting, weight loss 	<ul style="list-style-type: none"> • Pain 2–4 hr. after meals and midmorning, midafternoon, middle of night; pain is periodic and episodic • Pain relief with antacids and food; occasional nausea and vomiting
Recurrence rate	<ul style="list-style-type: none"> • High 	<ul style="list-style-type: none"> • High
Complications	<ul style="list-style-type: none"> • Hemorrhage, perforation, outlet obstruction, intractability 	<ul style="list-style-type: none"> • Hemorrhage, perforation, obstruction

1.1.4. Diagnostic measures

The gastroduodenal ulcers can be diagnosed through a complete history, physical examination, Complete Blood Cell Count (CBC), upper gastrointestinal endoscopy with biopsy, *Helicobacter pylori* testing. Endoscopy is the most accurate diagnostic procedure and allows for direct viewing of the gastric and duodenal mucosa (Fig.1.2).

The Complete blood cell count may indicate low level of Hb and Ht due to chronic bleeding. *Helicobacter pylori* results are referred to as positive or negative. Differential diagnostic includes acute cholelithiasis, cholelith syndrome, myocardial infection

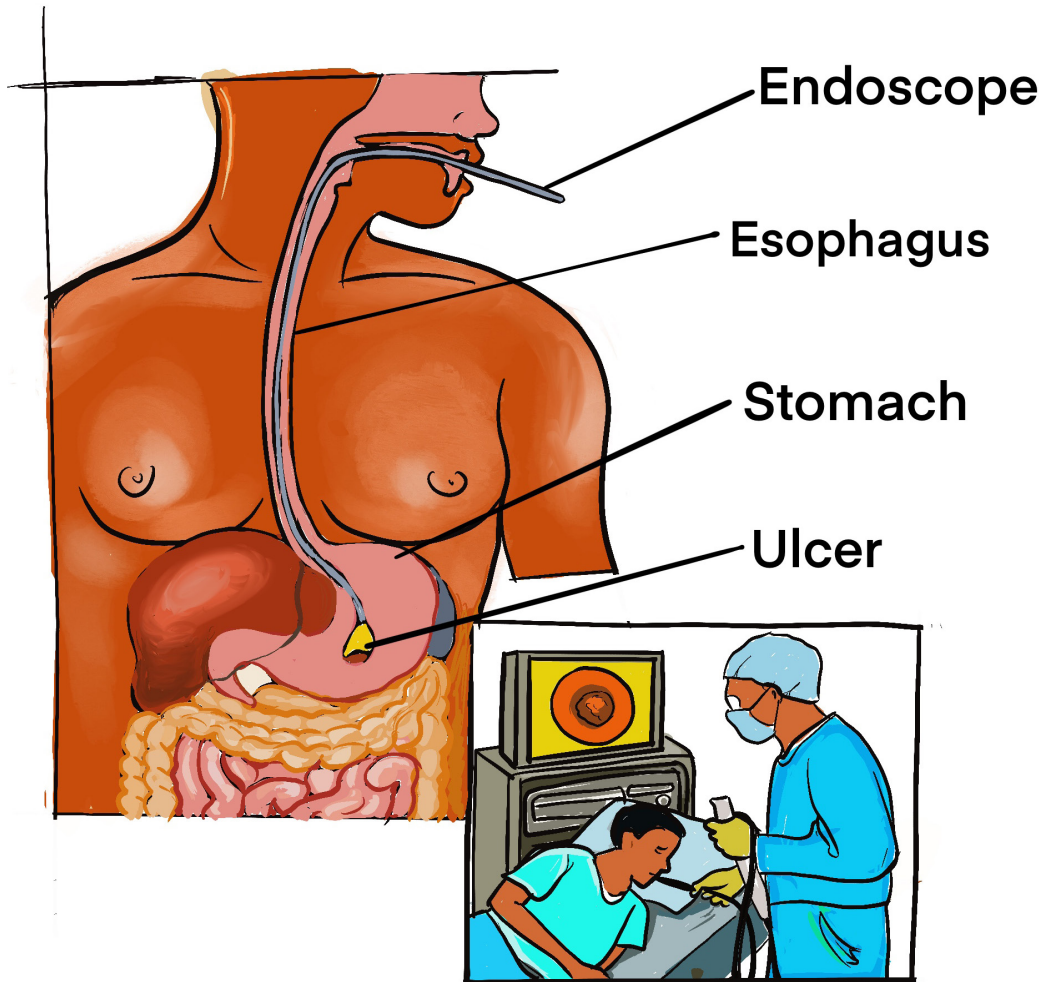


Figure 1.2: Esophagogastroduodenoscopy (EGD) directly visualizes the mucosal lining of the stomach with a flexible endoscope. Ulcers or tumors can be directly visualized and biopsies taken. (Lewis et.al 2012)

Self-assessment 1.1

1. Briefly explain the pathophysiology of gastroduodenal ulcers?
2. Identify other diseases that would mimic the symptoms of gastroduodenal ulcers?
3. How would reduce the anxiety of the patient caused by the fear of endoscopy?

1.2. The management of gastroduodenal ulcers

Learning Activity 1.2

...Continuation of S.D case study

After different investigations, the medical doctor confirmed that the police officer Mr. S.D is suffering from Gastroduodenal ulcers. Regarding the treatment, Mr. S.D has received two units of packed RBCs and intravenous fluids. Oral omeprazole (40 mg BID) was ordered and when he was in endoscopy they managed to stop the bleeding.

Questions related to the case study

- 1) What is the surgical treatment plan adopted by the medical doctor for this patient?
- 2) In group discuss the different medication prescribed to this patient
- 3) List potential complications which may happen to this police officer

1.2.1. The treatment plan of Gastroduodenal ulcers

Medications to treat peptic ulcer include:

- Proton pump inhibitors (PPI): These drugs reduce acid, which allows the ulcer to heal (e g: nexium).
- Histamine receptor blockers (H2 blockers): These drugs also reduce acid production (e g: Tagamet).
- Antibiotics: These medications kill bacteria (e g: Amoxicillin).
- Protective medications: Like a liquid bandage, these medications cover the ulcer in a protective layer to prevent further damage from digestive acids and enzymes (e g: Carafate).
- Several treatment options are combined to cure H. pylori without recurrence. Triple therapy has the best eradication rate
- Endoscopy procedure treatment:
 - Doctor may treat peptic ulcers during an endoscopy procedure by injecting medications
 - Doctor can also use a clamp or cauterization (burning tissue) to seal it off and stop the bleeding.

To eradicate the H pylori infection dual or triple therapy is recommended as indicated in table 1.2.

Table 1.2. Medication regimen options for H. pylori infection

Type of therapy	Examples of therapy options
Triple therapy: Two antibiotics + proton pump inhibitor	<ul style="list-style-type: none">• Amoxicillin + clarithromycin + omeprazole• Amoxicillin + clarithromycin + lansoprazole
Dual therapy: Antibiotic + proton pump inhibitor	<ul style="list-style-type: none">• Clarithromycin + omeprazole• Amoxicillin + lansoprazole)• Clarithromycin + H2 antagonist

1.2.2. Associate nurse decision making

In the hospital, the associate nurse will perform tasks that are delegated by registered nurses. The primary focus of care for peptic ulcer disease is educating patients. The teaching guide will include detail the following:

- Describe dietary modifications
- Explain the rationale for avoiding cigarettes
- Emphasize the need to reduce or eliminate alcohol ingestion
- Explain the rationale for avoiding OTC drugs unless approved by the patient's health care provider.
- Explain the rationale for not interchanging brands of antacids and H2-receptor blockers that can be purchased OTC without checking with the health care provider
- Emphasize the need to take all medications as prescribed
- Explain the importance of reporting any of the following:
- Describe the relationship between symptoms and stress. Stress reducing activities and relaxation strategies are encouraged.
- Encourage patient and caregiver to share concerns about lifestyle changes and living with a chronic illness.

1.2.3. Complications of gastroduodenal ulcers

Perforation, abscess of the appendix, and peritonitis are major complications of gastroduodenal ulcer. With perforation, the pain is severe, and temperature is elevated to at least 37.7°C.

Self-assessment 1.2

Mr. S.M a patient on your department unit, has a duodenal ulcer. His wife runs to the nursing station and says that you need to help her husband, he is in terrible pain. As you enter the room, you see Mr. SM bent knee-to-chest position on the bed. He is crying and says he has excruciating abdominal pain.

- 1) What additional data would you gather?
- 2) What emotional support would you offer to Mrs. SM?
- 3) After orders are obtained, what actions will you anticipate implementing under supervision

End Unit assessment 1

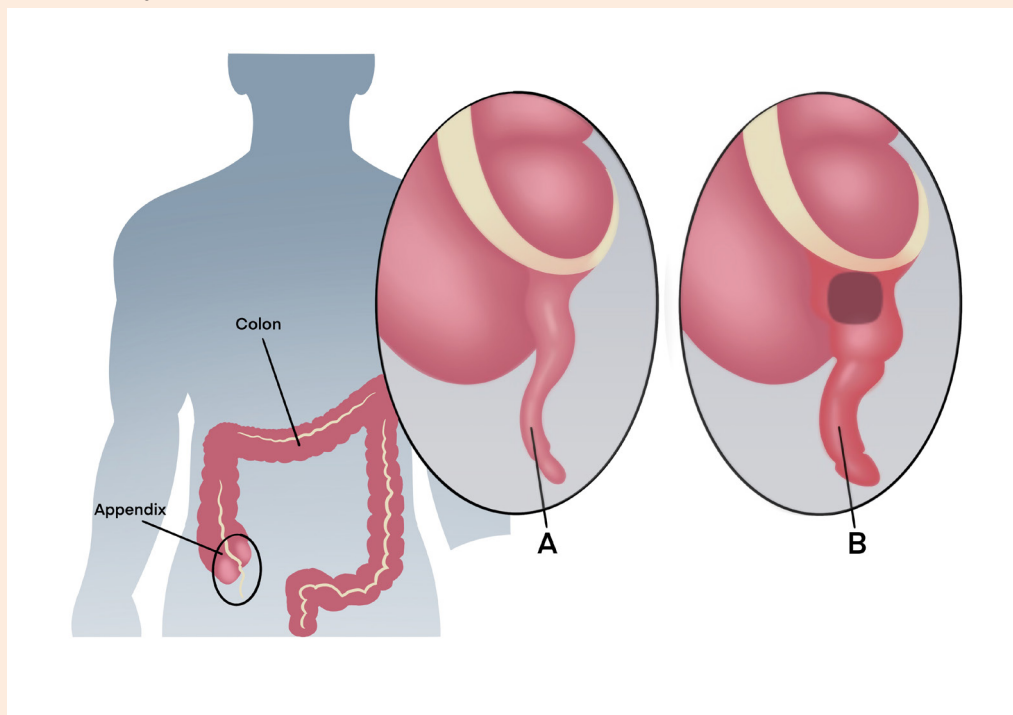
- 1) What are the most frequent symptoms of Gastroduodenal ulcers?
- 2) What are the diagnostic measures of Gastroduodenal ulcers?
- 3) The nurse is teaching the client and her family about possible causes of peptic ulcers. How does the nurse explain ulcer formation? Choose the best answer.
 - a) Caused by a stressful lifestyle and other acid-producing factors such as *Helicobacter pylori*
 - b) Inherited within families and reinforced by bacterial spread of *Staphylococcus aureus* in childhood
 - c) Promoted by factors that tend to cause over secretion of acid, such as excess dietary fats, smoking, and *H. pylori*
 - d) Promoted by a combination of possible factors that may result in erosion of the gastric mucosa, including certain drugs and alcohol
- 4) Duodenal and gastric ulcers have similar as well as differentiating features. What are characteristics unique to duodenal ulcers (select all that apply)?
 - a) Pain is relieved with eating food.
 - b) They have a high recurrence rate.
 - c) Increased gastric secretion occurs.
 - d) Associated with *Helicobacter pylori* infection.
 - e) Hemorrhage, perforation, and obstruction may result.
 - f) There is burning and cramping in the midepigastric area.
- 5) What are the dietary modifications would you recommend a patient with gastroduodenal ulcers?

Key Unit competence

Take appropriate decision on appendicitis conditions.

Introductory activity 2.0

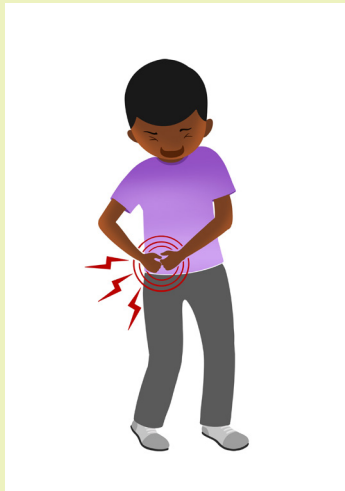Observe the images A and B below illustrating the structures of appendix in human body.



- 1) Is there any difference between two appendixes?
- 2) Which one of these two would reflect the normal structure of appendix in the human body?
- 3) Describe the abnormalities that you have observed.
- 4) What do you think can cause the abnormalities that you have observed?
- 5) What are the manifestations of the observed abnormalities in the human body?
- 6) How can health personnel identify these abnormalities?
- 7) How can these abnormal structures be corrected?

2.1. Description of appendicitis

Learning Activity 2.1



M.H, a-13-year-old boy with history of constipation comes into the emergency of referral hospital for severe abdominal pain. M.H reports that his abdomen hurts for the past 24 hours. He notes that he initially suffered from mild pain around his umbilicus last night and this morning he reported that the pain has migrated to his right lower quadrant. He tells the nurse that the *pain just keeps getting worse and it* is associated with nausea, vomiting and fever (39 degrees Celsius). Upon physical assessment, M.H doesn't allow anyone auscultate or palpate his abdomen because of the pain. After 10 minutes he allowed the nurse to do physical assessment. He is quite tender to mild palpation in the right lower quadrant and he has muscle guarding. M.H prefers to lie still with the right leg flexed. The medical doctor ordered blood sample to check the number of WBCs. He also ordered ultrasound and CT scan. The blood test revealed elevated WBC (Full Blood Cell) and neutrophil counts. An ultrasound and computed tomography (CT) scan revealed an enlargement in the area of the cecum and appendicitis was confirmed. Based on the case study narrated above, answer to the following questions.

Questions related to the case study

- 1) Identify the biography of M.H
- 2) What is the medical history of M.H?
- 3) Describe the signs and symptoms of M.H
- 4) What are the aggravating and relieving factors for M.H?
- 5) What are the differential diagnosis M.H?

2.1.1. Definition of appendicitis

Appendicitis is inflammation of the appendix, a narrow blind tube that extends from the inferior part of the cecum. Appendicitis, inflammation of the vermiform appendix, is a common cause of acute abdominal pain and most common reason for emergency abdominal surgery. It occurs at any age, but it is more common in adolescents and young adults and slightly more common in males than females

2.1.2. Causes and pathophysiology of appendicitis

Because of the small size of the appendix, obstruction may occur, causing inflammation and making it susceptible to infection. The obstruction is often caused by a faecalith or hard mass of faeces. Other obstructive causes include a calculus or stone, a foreign body, inflammation, a Tumor, parasites (e.g. pinworms) or oedema of lymphoid tissue. Hereditary and family tendencies of appendicitis have been noticed. Following obstruction, the appendix distends with fluid secreted by its mucosa. As pressure within the lumen of the appendix increases, blood supply is impaired, leading to inflammation, edema, ulceration and infection.

2.1.3. Signs and symptoms of appendicitis

Signs and symptoms of appendicitis include fever, generalized pain in the upper abdomen. Within hours of onset, the pain usually becomes localized starts on the periumbilical area to the right lower quadrant at McBurney's point, midway between the umbilicus and the right iliac crest. This is one of the classic symptoms of appendicitis. Nausea, vomiting, and anorexia are also usually associated. Physical examination reveals slight abdominal muscular rigidity (guarding), normal bowel sounds, and local rebound tenderness (intensification of pain when pressure is released after palpation) in the right lower quadrant of the abdomen. The pain is aggravated when patient straightens the leg, coughs, walks and makes any shaking movement. The patient may keep the right leg flexed for comfort.

! Consideration for practice

- Sudden relief of preoperative pain may signal rupture of the distended and edematous appendix.
- Assess abdominal status frequently, including distension, bowel sounds and tenderness: Increasing generalized pain, a rigid, boardlike abdomen and abdominal distension may indicate developing peritonitis.

McBurney's Point

2/3 of the way from
umbilicus to ASIS

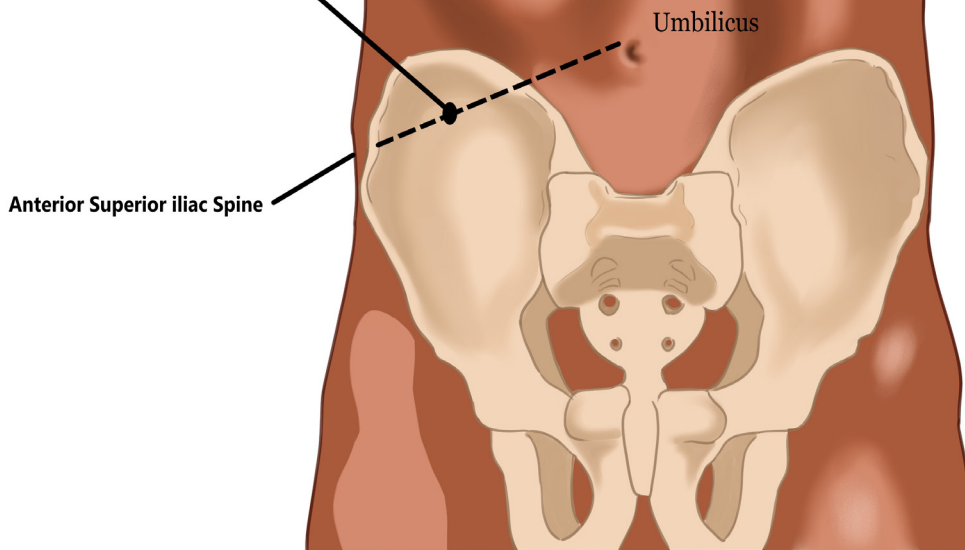


Figure 2.1. McBurney's point

2.1.4. Diagnostic measures

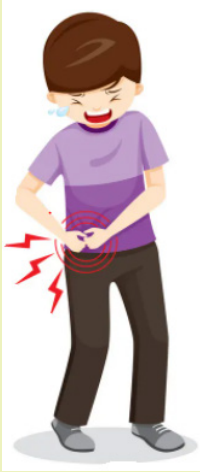
The appendicitis can be diagnosed through a complete history, physical examination, and a differential WBC count. The WBC count is mildly moderately elevated in most cases. CT scan is the preferred diagnostic procedure, but ultrasound is also used. A urinalysis is done to rule out genitourinary conditions that mimic the manifestations of appendicitis. Other differential diagnostic includes intestinal obstruction, inflammation and stones of gall bladder, stones in urinary organs such as ureter, ruptured ovarian follicle, a ruptured tubal pregnancy, perforation of stomach or duodenal ulcer and inflammation of the right colon

Self-assessment 2.1

- 1) Who are people most likely to develop appendicitis?
- 2) Among the cells of WBC, which ones would increase in case of appendicitis?.

2.2. The management of appendicitis

Learning Activity 2.2



...Continuation of M.H case study.

After different investigations, the medical doctor confirmed that M.H is suffering from appendicitis. The patient was kept NPO and the surgery (appendectomy) was decided on him but prior to surgery he prescribed intravenous fluids, antibiotics. After the surgery, the surgeon noted in the post-surgery report that there was no perforation or abscess of the appendix, and no signs of peritonitis. The boy stayed in hospital for 3 days and was discharged home without pain and normal vital signs. He was requested to report the nearest health facility after 3 days for wound dressing.

Questions related to the case study

- 1) What is the surgical treatment plan adopted by the medical doctor for this patient?
- 2) What are other collaborative management was followed?
- 3) Discuss in group the examples of different medication prescribed to this patient

2.2.1. The treatment plan

The patient is kept NPO, and surgery (check appendectomy collaboration care in box 2.1) is done immediately unless there is evidence of perforation or peritonitis. Medications prior to surgery, intravenous fluids are given to restore or maintain vascular volume and prevent electrolyte imbalance. Antibiotic therapy with a third-generation cephalosporin effective against many gram-negative bacteria, such as cefotaxime (Cefotaxime Sandoz), ceftazidime (Fortum) or ceftriaxone (Rocephin) is initiated prior to surgery. The antibiotic is repeated during surgery and continued for at least 48 hours postoperatively. Post-operative analgesic medications are administered as prescribed.

Following an uncomplicated appendectomy, the person is often discharged either the day of, or the day following, surgery. Postoperative teaching includes:

- Wound or incision care, including hand hygiene and dressing change procedures as indicated.
- Instructions to report fever, increased abdominal pain, swelling, redness, drainage, bleeding or warmth of the operative site to the doctor.

- Activity limitations (e.g. lifting, driving), if any.
- When it is appropriate to return to work.

Summary of appendectomy care is indicated in table 2.1

Table 2.1: Appendectomy collaborative care		
Preoperative	Perioperative	Postoperative
<ul style="list-style-type: none"> • NPO • IV fluids • Vital signs monitoring • No analgesia, pain needs to be monitored, as it indicates what is happening. Regular analgesia only before operation • No heat: increases the risk of perforation and rupture of the appendix • No laxatives and enema: induced peristalsis increases the risk of perforation and rupture 	<p><i>Intraoperative</i></p> <ul style="list-style-type: none"> • IV Fluids • Vital signs monitoring • Count instrument and swabs before and after surgery 	<p><i>Postoperative</i></p> <ul style="list-style-type: none"> • Antibiotics mainly if perforation • Analgesics • Dressing the wound • Bath assistance • Encourage patients to mobilize to avoid embolism • Check the bowel sounds (returned between 8-48hours) • Start food in high fibre slowly after bowel sounds can be heard

2.2.2. Associate nurse decision making

An associate nurse who receives a patient with signs and symptoms of appendicitis must refer the case to the next level for adequate management. In the hospital, the associate nurse works under supervision of registered nurses and they will discuss the appropriate nursing care plan.

2.2.3. Complications of appendicitis

Most patients recover quickly after an appendectomy and frequently are discharged from the hospital after few days. Preventing complications during the perioperative period is a primary nursing care goal. Perforation and peritonitis are the most likely preoperative complications. With perforation, the pain is severe, and temperature is elevated to at least 37.7°C. Postoperative complications include wound infection, abscess and possible peritonitis.

Self-assessment 2.2

- 1) What is the rationale of avoiding the use of warm/heating pads to relieve the pain resulting from appendicitis?
- 2) Explain the treatment options for a patient with appendicitis

End Unit assessment 2

- 1) Within hours of onset, the pain of appendicitis usually becomes localized starts on the _____ area to the _____ quadrant.
- 2) What are the diagnostic measures of appendicitis?
- 3) The patient has persistent and continuous pain at McBurney's point. The nursing assessment reveals rebound tenderness and muscle guarding with the patient preferring to lie still with the right leg flexed. What should the nursing interventions for this patient include? Choose the best answer
 - a) Laxatives to move the constipated bowel
 - b) NPO status in preparation for possible appendectomy
 - c) Parenteral fluids and antibiotic therapy for 6 hours before surgery
 - d) NGT (Nasogastric Tube) inserted to decompress the stomach and prevent aspiration
- 4) Appendicitis may occur:
 - a) After complications of an episode of flu
 - b) After complications of a viral infection of the digestive
 - c) After opening to the appendix becomes blocked by stool
 - d) After an enema to evacuate the stool
- 5) If you suspect the appendicitis, what type of medicine should you not take?
 - a) Analgesics
 - b) Laxatives
 - c) Anti-inflammatory
 - d) Allergy medicines

6) BA 19-year-old student in her second year of a dental degree. BA arrives at the emergency department at 0200hrs. She presents a general lower abdominal pain which started the previous evening. She is also nauseated and reports episodes of vomiting. The physical assessment reveals the T 37.8 °C, R 16, BP 110/70; abdomen flat and guarded. BA WBC was 14000/mm³.

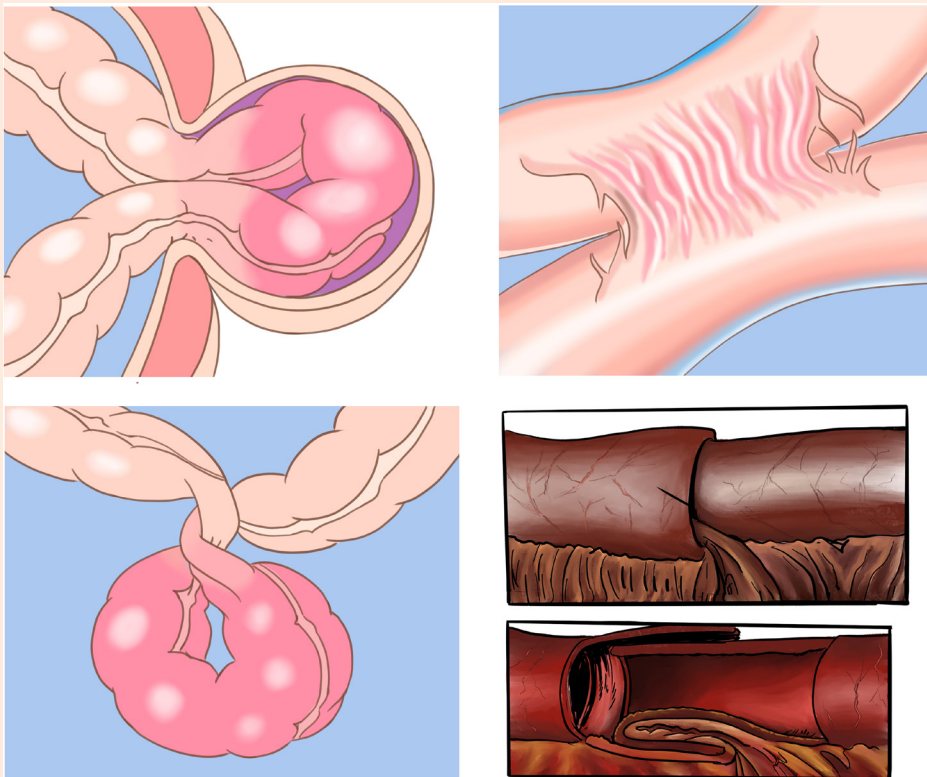
- a) What are the missing characteristics/features of the abdominal pain to confirm appendicitis?
 - b) What are the disturbed needs of BA?
 - c) Is appendectomy indicated for this patient? Justify your response
- 7) List the complications of appendicitis

Key Unit competence

Take appropriate decision on intestinal obstruction conditions.

Introductory activity 3.0

Observe the segments of the intestines presented in figure A, B, C and D and respond to the questions below.



- 1) What do you think is happening to these segments of the intestines?
- 2) Is there any difference between four figures? Describe the differences observed.
- 3) Reference to what you learnt in anatomy and physiology, what are the implications of such structures on food digestion?
- 4) What are other manifestations of such structures to the human body?
- 5) How can health personnel identify these structures?
- 6) How can these segments be corrected?

3.1. Description of intestinal obstruction

Learning Activity 3.1

L.A, a 59-year-old woman was brought to the hospital with a 3-day history of complete constipation and faeculent vomiting. She had no other medical or surgical history and was not taking any regular medications. She lived at home with sister and required assistance with several activities of daily living, however, she was able to eat on her own. On examination, her abdomen was extended and mildly tender in the right iliac fossa, but there was no guarding or peritonism. Chest and cardiac examination revealed tachycardia (115bpm), BP 139/102 mmHg, RR 18, T0 37.10C and saturation 98% on room air. The medical doctor prescribed the following investigations: blood sample, abdomen x-rays and CT scan. The results showed an increase of WBCs, urea and creatinine. A relatively gasless abdomen with few dilated loops of small bowel was observed in the results of X-rays. The CT scan showed small bowel obstruction within the mid small bowel loop with the possibility of ischaemia of the small bowel loop. There was no evidence of bowel operation.

Questions related to the case study

- 1) What is the intestinal obstruction?
- 2) Briefly describe the pathophysiology of intestinal obstructions
- 3) What are the key signs and symptoms of intestinal obstructions highlighted in the case study?

3.1.1. Definition of intestinal obstruction

Intestinal obstruction occurs when the contents of intestines fail to pass through the bowel lumen. The obstruction may take place in both small or large intestines and can be partial or complete.

3.1.2. Causes and pathophysiology of intestinal obstruction

The two types of intestinal obstruction are mechanical and non-mechanical. Mechanical obstruction occurs when a blockage occurs within the intestine from conditions causing pressure on the intestinal walls such as adhesions (B), twisting or volvulus (C) of the bowel, intussusception (D), or strangulated hernia (A). Non mechanical obstruction may result from a neuromuscular or vascular disorder. Paralytic ileus (lack of intestinal peristalsis and bowel sounds) is the most common form of non-mechanical obstruction.

When an obstruction occurs, fluid, gas, and intestinal contents accumulate proximal to the obstruction, and the distal bowel collapses.

The proximal bowel becomes increasingly distended, and intraluminal bowel pressure rises, leading to an increase in capillary permeability and extravasation of fluids and electrolytes into the peritoneal cavity.

This accumulation of fluids in intestines and in peritoneal cavity causes a severe reduction in circulating blood volume, hence hypotension, hypovolemic shock and bowel ischemia.

When the distension is severe the segment of the bowel becomes gangrenous a condition known as intestinal strangulation or intestinal infarction (figure 3.1)

If it is not corrected quickly, the bowel will rupture, leading to infection, septic shock, and death. If the obstruction is below the proximal colon or in the large bowel which is less common and not usually as dramatic as small-bowel obstruction, dehydration occurs more slowly because of the colon's ability to absorb fluid and distend well beyond its normal full capacity.

If the blood supply to the colon is cut off, the patient's life is in jeopardy because of bowel strangulation and necrosis

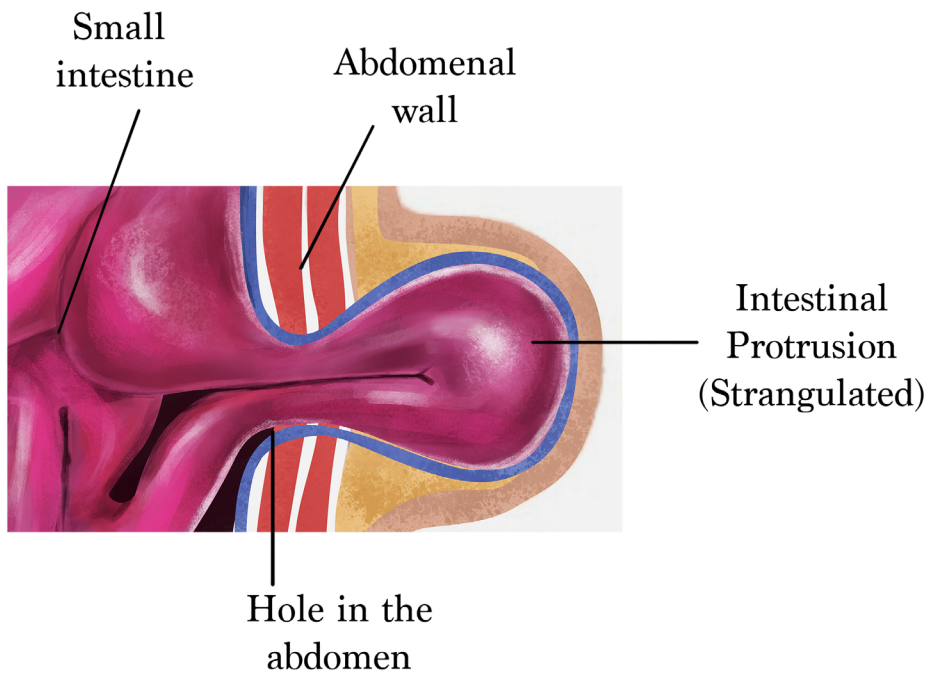


Figure 3.1: Intestinal strangulation

3.1.3. Signs and symptoms of intestinal obstruction

The clinical manifestations of intestinal obstruction vary, depending on its location as displayed in table.

Table 3.1 CLINICAL MANIFESTATIONS OF SMALL AND LARGE INTESTINAL OBSTRUCTIONS

Clinical Manifestations	Small Intestine	Large Intestine
Onset	Rapid	Gradual
Vomiting	Frequent and copious,	Late manifestation
Pain	colicky, cramplike, intermittent	Low-grade, cramping abdominal pain
Bowel movement	Feces for a short time	Absolute constipation
Abdominal distension	Dependent upon location of obstruction, minimal to greatly increased	Greatly increased

! Consideration for practice

- Abdominal tenderness and rigidity are usually absent unless strangulation or peritonitis has occurred.
- Auscultation of bowel sounds reveals high-pitched sounds above the area of obstruction. Bowel sounds may also be absent.
- The patient often notes borborygmi (audible abdominal sounds produced by hyperactive intestinal motility).
- The patient's temperature rarely rises above 37.8° C unless strangulation or peritonitis occurs.
- Promptly report any acute increase in abdominal, groin, perineal or scrotal pain.
- An abrupt increase in the intensity of pain may indicate bowel ischaemia due to strangulation.

3.1.4. Diagnostic measures of intestinal obstruction

A thorough history and physical examination. CT scans, abdominal x-rays, Sigmoidoscopy or colonoscopy may provide direct visualization of an obstruction in the colon. A FBC and blood chemistries may be performed. An elevated WBC count may indicate strangulation or perforation. Elevated haematocrit values may reflect hemoconcentration. Decreased hemoglobin and hematocrit values may indicate bleeding from a neoplasm or strangulation with necrosis. Serum electrolytes, BUN, and creatinine are monitored frequently to assess the degree of dehydration.

Self-assessment 3.1

- 1) List different exams performed in order to diagnose intestinal obstruction condition
- 2) What is the indication of frequent monitoring of electrolytes, BUN and creatinine on patient suffering of intestinal obstruction?

3.2. The management of intestinal obstruction

Learning Activity 3.2

...Continuation of L.A case study

After different investigations, the medical doctor confirmed that LA is suffering from intestinal obstruction. Intravenous catheter was inserted and IV fluids administered; a decompressive nasal gastric tube was put in place and later alone patient was taken to the theatre for surgery.

A laparotomy was performed and proved to be a single potato, measuring 4×3cm, swallowed without chewing. The potato was extracted. In post-operative, the medical doctor prescribed antibiotics, anti-emetics and pain control medications and the patient was recovered well with no complications. The patient was discharged with written letter to her sister regarding dietary advice. The patient was subsequently followed up 8 weeks postoperatively and she was well.

Questions related to the case study

- 1) What is the pre and post-operative treatment plan of Mrs. L.A?

3.2.1. The treatment plan of intestinal obstruction

The management of a bowel obstruction focuses on relieving the pressure and obstruction and providing supportive care. The intestine is decompressed by NG tube insertion and keeping the patient. Nothing by mouth (NPO), the dehydration and electrolytes imbalances are corrected by administering fluid and electrolytes. Surgery may be necessary to relieve a mechanical obstruction or if strangulation is suspected. In post-surgery mouth care is performed, medications such as antibiotics, antiemetics, and analgesics are administered. A teaching plan is also elaborated.

Include the following topics when teaching a person with intestinal obstruction in preparation for home care:

- Wound care
- Activity level,
- Return to work and any other recommended restrictions
- Recommended follow-up care
- Recurrent obstructions, explain their cause, early identification of manifestations and possible preventive measures.

3.2.2. Associate nurse decision making

An associate nurse who receives a patient with signs and symptoms of intestinal obstruction must refer the case to the next level for adequate management. In the hospital, the associate nurse works under supervision of registered nurses and they will discuss the appropriate nursing care plan.

3.2.3. Complications of intestinal obstruction

Small intestines obstructions: Hypovolaemia and hypovolaemic shock with multiple organ dysfunction is a significant complication of bowel obstruction and can lead to death. Renal insufficiency from hypovolaemia leads to acute kidney injury or dysfunction. Pulmonary ventilation may be impaired because abdominal distension elevates the diaphragm, impeding respiratory processes. Strangulation associated with incarcerated hernia or volvulus impairs the blood supply to the bowel. Gangrene may rapidly result, causing bleeding into the bowel lumen and peritoneal cavity and eventual perforation. With perforation, bacteria and toxins from the strangulated intestine enter the peritoneum and, potentially, the circulation, resulting in peritonitis and possible septic shock. Strangulation greatly increases the risk of mortality.

Large intestines: If the ileocaecal valve between the small and large intestines is competent, distension proximal to the obstruction is limited to the colon itself. This is known as a *closed-loop obstruction*. It leads to massive colon dilation as the ileum continues to empty gas and fluid into the colon. Increasing pressure within the obstructed colon impairs circulation to the bowel wall. Gangrene and perforation are potential complications.

Self-assessment 3.2

Mrs. LS is admitted for abdominal pain. She has a history of abdominal surgery. Her abdomen is distended, firm, and tender to touch. She states that she feels nauseated.

- 1) Is Mrs. L.S at risk for developing an intestinal obstruction?
- 2) How would the nurse know if Mrs. LS is at risk of developing a small-bowel obstruction?

End Unit assessment 3

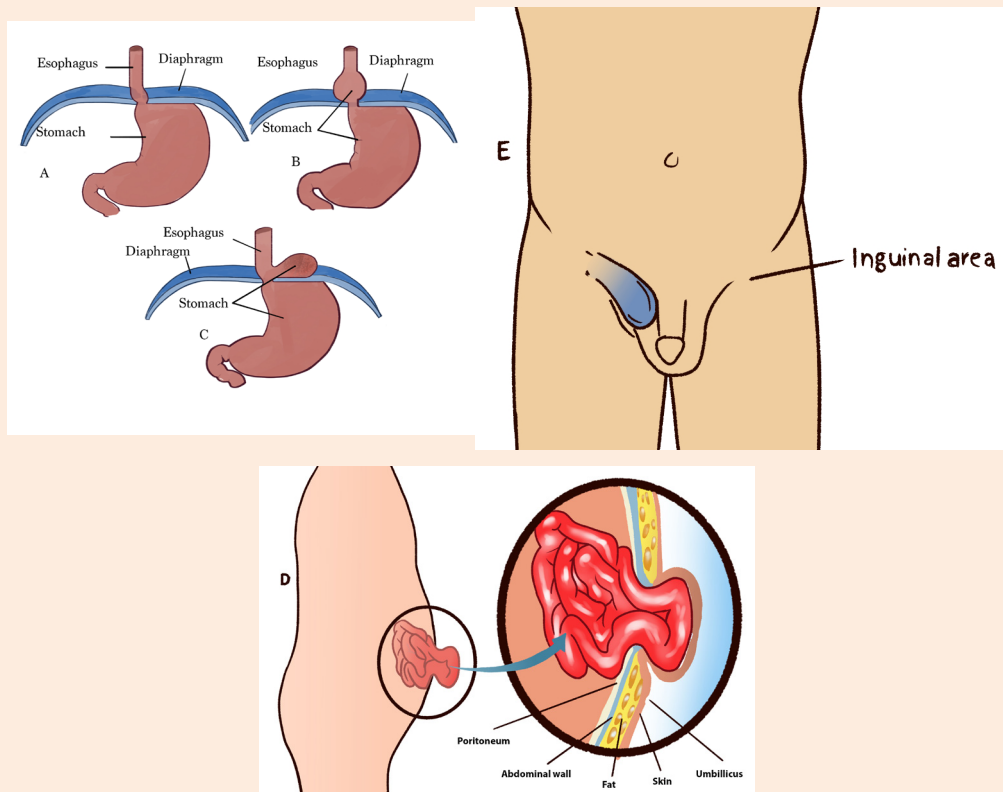
- 1) What are the common causes of intestinal obstruction?
- 2) What are the most common types of intestinal obstructions?
- 3) What are the predicted complications on patient with intestinal obstruction?

Key Unit competence

Take appropriate decision on Hernia

Introductory activity 4.0

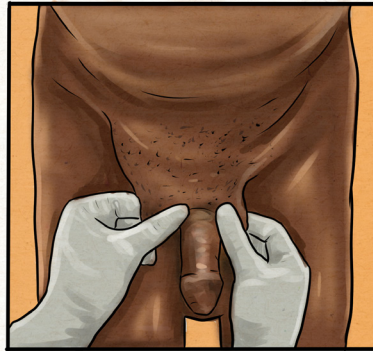The below images illustrate different structures including esophagus, stomach, diaphragm (A, B, C) umbilicus (D) and inguinal area (E). Observe them and respond to the questions attached.



- 1) Identify normal and abnormal structures among the images above
- 2) What is the common characteristic of the abnormal structures?
- 3) What could be the causes of such abnormalities?
- 4) What are the manifestations of such abnormalities in the human body?
- 5) How can health personnel identify or notice these abnormalities?
- 6) How can these abnormalities be corrected?

4.1. Abdominal hernias

Learning Activity 4.1



Mr. Y.A. 65 years old male, a laborer in a sawmill with low socioeconomic status visits the hospital with chief complaints of swelling of about 10cm in right groin since 3 years and pain in the right groin since 6 months. In the history, patient was apparently well 3 years back, he noticed a swelling in right groin while coughing which was initially small size (3cm) gradually increasing to present size and reaching up to the scrotum. Mr. Y.A states that the swelling increases when standing, coughing and lifting heavy weights. It decreases on lying down and disappear on manipulation (pushing it using his fingers). Y.A has a history of chronic cough with sputum since 20years but no history of chronic constipation or urinary problems. Mr. Y.A is a known case of COPD on bronchodilators since 20 years, has habit of smoking, non-alcoholic, non-vegetarian diet, bowel and bladder habits-regular. No history of similar history in his family. He regular takes levasalbutamol inhaler since 20 years. No history of any allergy. On physical examination; normal vital signs, a swelling of size 6x3cm is present above and medial to the pubic tubercle extending into the scrotum up to upper pole of right testis.

After taking history and performing physical exam, the health personnel confirmed inguinal hernia and planned a surgical treatment.

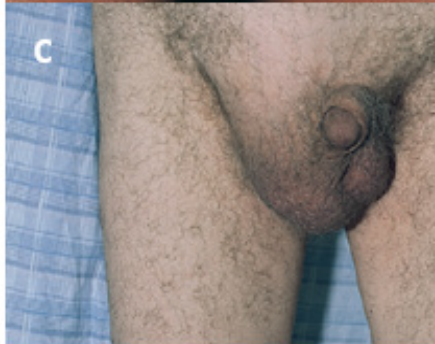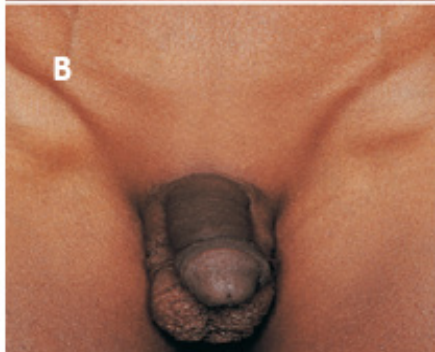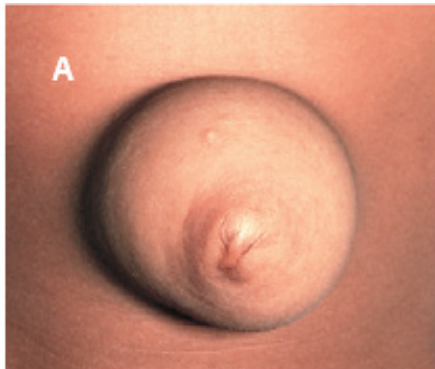
Questions related to the case study.

- 1) Based on the history of Y.A, what are the contributing factors of inguinal hernia?
- 2) What are the signs and symptoms of inguinal hernia?
- 3) How inguinal hernia be diagnosed?
- 4) What is the treatment adopted by the health personnel?

4.1.1 Definition of abdominal hernias

A **hernia** is an abnormal protrusion of an organ or structure through a weakness or tear in the wall of the cavity normally containing it. Abdominal hernias are defined as the abnormal protrusion of intra-abdominal contents through congenital/acquired areas of weakness in the abdominal wall

4.1.2 Types of abdominal hernias



The common abdominal hernias include inguinal, femoral, umbilical and ventral or incisional.

Abdominal hernias are caused by a weakness in the abdominal wall along with increased intra-abdominal pressure, such as the pressure from coughing, straining, and heavy lifting.

The **inguinal hernia** is the most common type of hernia and occurs at the point of weakness in the abdominal wall where the spermatic cord (in men) or the round ligament (in women) emerges (fig 4.1 C). Inguinal hernias are more common in men.

A **femoral hernia** occurs when there is a protrusion through the femoral ring into the femoral canal. It appears as a bulge below the inguinal ligament. It easily becomes strangulated. It occurs more often in women (fig. 4.1 B).

The **umbilical hernia** occurs when the rectus muscle is weak (as with obesity) or the umbilical opening fails to close after birth (fig 4.1 A). Umbilical hernias are seen most often in obese women and in children. They are caused by a failure of the umbilical orifice to close.

Figure 4.1: A, Umbilical hernia. B, Femoral hernias (note swelling below the inguinal ligaments). C, Right inguinal

Ventral or incisional hernias are due to weakness of the abdominal wall at the site of a previous incision (fig 4.2). They occur most commonly in patients who are obese, have had multiple surgical procedures in the same area, or have had inadequate wound healing because of poor nutrition or infection.

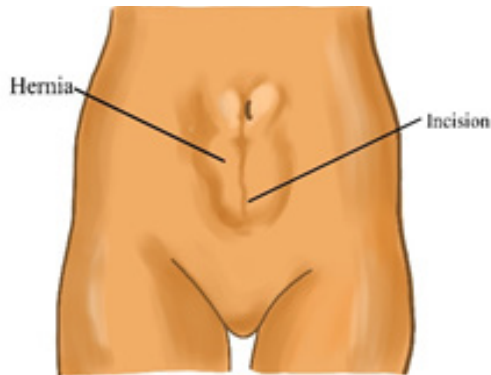


Figure 4.2 Incisional or Ventral hernia

Hernias that easily return to the abdominal cavity are called *reducible*. The hernia can be reduced manually or may reduce spontaneously when the person lies down. If the hernia cannot be placed back into the abdominal cavity, it is known as *irreducible* or *incarcerated*. In this situation the intestinal flow may be obstructed. When the hernia is irreducible and the intestinal flow and blood supply are obstructed, the hernia is strangulated. The result is an acute intestinal obstruction.

4.1.3 Clinical manifestations of abdominal hernias

An abdominal hernia may be readily visible; an abnormal bulging can be seen in the affected area of the abdomen, especially when straining or coughing. There may be some discomfort as a result of tension. If the hernia becomes strangulated, the patient will have severe pain and symptoms of a bowel obstruction such as vomiting, cramping abdominal pain, and distention. Strangulated hernias are painful and inflamed hernias that cannot be reduced, they require emergency surgery.

4.1.4. Diagnostic measures

Abdominal hernias are mainly diagnosed based on history, physical examination and ultrasound.

4.1.5 Therapeutic Measures

Treatment options include no treatment, observing the hernia, using short-term support devices, or surgery to cure the hernia. A supportive truss or brief applies pressure to keep the reduced hernia in place. Emergency surgery is needed for strangulation or the threat of bowel obstruction. Surgical repair is recommended for inguinal hernias. Surgical procedures are most often done laparoscopically and include hernioplasty (open or laparoscopically) or herniorrhaphy (open hernia repair).

Herniorrhaphy involves making an incision in the abdominal wall, replacing the contents of the hernial sac, sewing the weakened tissue, and closing the opening.

Hernioplasty involves replacing the hernia into the abdomen and reinforcing the weakened muscle wall with wire, fascia, or mesh. Bowel resection or a temporary colostomy may be necessary if the hernia is strangulated.

Postoperative Care

Care following inguinal hernia repair is generally similar to any abdominal postoperative care. Patients can perform deep breathing to keep lungs clear postoperatively but should avoid coughing. Coughing increases abdominal pressure and could affect the hernia repair. Teach patients to splint the incision and keep their mouths open when coughing or sneezing are unavoidable. The male patient may experience swelling of the scrotum. Ice packs and elevation of the scrotum may be ordered to reduce the swelling. Because most patients are discharged the same day of surgery, they are taught to change the dressing and report difficulty urinating, bleeding, and signs and symptoms of infection, such as redness, incisional drainage, fever, or severe pain. The patient is also instructed to avoid lifting, driving, or sexual activities for 2 to 6 weeks. Most patients can return to nonstrenuous work within 2 weeks.

After a hernia repair, the patient may have difficulty voiding. Measure intake and output and observe for a distended bladder. Scrotal edema is a painful complication after an inguinal hernia repair. A scrotal support with application of an ice bag may help relieve pain and edema. Encourage deep breathing, but not coughing.

4.1.6 Associate nurse decision making

The associate nurse has to recognize the signs and symptoms of hernias and the strangulated hernias for better referring. A post-operative teaching plan is also important and includes the above measures mentioned in post-operative care.

4.1.8 Complications

An incarcerated hernia may become strangulated if the blood and intestinal flow are completely cut off in the trapped loop of bowel. Strangulated hernias do not develop in adults very often. Incarceration leads to an intestinal obstruction and possibly gangrene and bowel perforation. Symptoms are pain at the site of the strangulation, nausea and vomiting, and colicky abdominal pain.

Self-assessment 4.1

- 1) What are the types of abdominal hernias?
- 2) Identify the common factors associated with abdominal hernia
- 3) What are the signs and symptoms of a complicated hernia?

4.2 Hiatal hernia

Learning Activity 4.2

P.F, a 56-year-old male consults the health facility experiencing pain about 2-3cm beneath his sternum and sharp pains in radiating towards his left shoulder. The pain varies in intensity and is increased immediately after eating spicy foods. After most meals, he suffers from mild heartburn. He said that the health personnel initially prescribed a two week course of Omeprazole, which alleviated the symptoms, but they returned after a few days.

The physical examination does not disclose any strong evidence. The patient is obese, lacks regular physical activities and poor diet. All other findings are within normal limits.

The medical doctor requested some diagnostic studies including an esophagram (barium swallow) and an endoscopy to visualize the lower esophagus. The results of these tests showed that there is a bulging mass in the low part of the esophagus and confirmed that it was the stomach prolapsing through the diaphragmatic esophageal hiatus i.e. hiatal hernia. Considering that omeprazole did not act before, the medical doctor proposed a surgical treatment that was scheduled in 2 weeks. While waiting for the surgical intervention, the patient was taught to observe some conservative treatment including:

- Elevation of head of bed
- Avoid reflux-inducing foods (fatty foods, chocolate, peppermint)
- Avoid alcohol
- Reduce or avoid acidic pH beverages (red wine, orange juice)
- Antacids were prescribed (omeprazole)

Questions related to the case study.

- 1) Identify the biography of the patient described in the case study
- 2) What is the medical history of patient described in the case study?
- 3) Describe the signs and symptoms that the patient present and are described in the case study
- 4) What are the diagnostic studies?
- 5) What was the proposed management plan?

4.2.1 Definition of hiatal hernia

Hiatal hernia is a condition in which the stomach slides up through the hiatus of the diaphragm into the thorax. It is also referred to as diaphragmatic hernia and esophageal hernia.

4.2.2 Causes and pathophysiology of Hernia

Many factors contribute to the development of hiatal hernia. Structural changes, such as weakening of the muscles in the diaphragm around the esophagogastric opening, occur with aging. Factors that increase intraabdominal pressure, including obesity, pregnancy, ascites, tumors, intense physical exertion, and heavy lifting on a continual basis, may also predispose patients to development of a hiatal hernia.

Hiatal hernias are classified into the following two types:

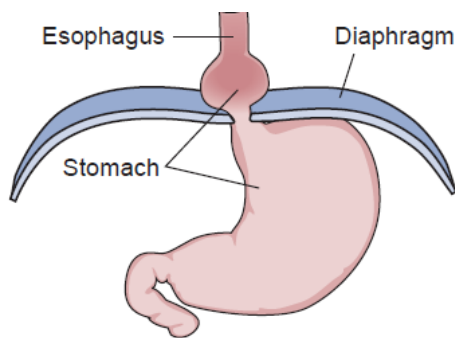


Figure 4.1 Sliding hiatal hernia.

1. Sliding: The junction of the stomach and the esophagus is above the diaphragm, and a part of the stomach slides through the hiatal opening in the diaphragm (Fig 4.1). This occurs when the patient is supine, and the hernia usually goes back into the abdominal cavity when the patient is standing upright. This is the most common type of hiatal hernia.

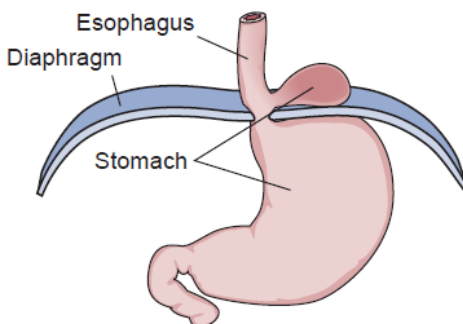


Figure 4.2 Rolling hiatal hernia

2. Paraesophageal, or rolling: The esophagogastric junction remains in the normal position, but the fundus and the greater curvature of the stomach roll up through the diaphragm, forming a pocket alongside the esophagus. Acute paraesophageal hernia is a medical emergency.

4.2.3 Signs and symptoms of Hernia

A small hernia may not produce any discomfort or require treatment. However, a large hernia can cause pain, heartburn, a feeling of fullness, or reflux (regurgitation), which can injure the esophagus with possible ulceration and bleeding.

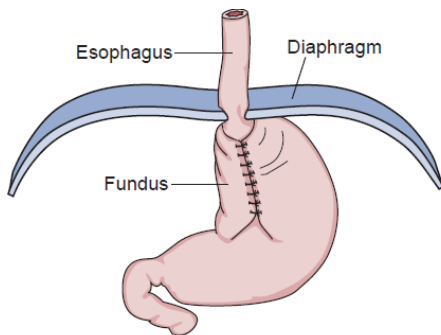
The chest pain can mimic angina and is described as burning; squeezing; or radiating to the back, neck, jaw, or arms. Complaints of chest pain are more common in older adults with hiatal hernia or gastro esophagus reflux (GERD) disease. Unlike angina, hiatal hernia and GERD-related chest pain is relieved with antacids.

4.2.4 Diagnostic measures

An x-ray studies such as an esophagram (barium swallow) may show the protrusion of gastric mucosa through the esophageal hiatus. Endoscopic visualization of the lower esophagus provides information on the degree of mucosal inflammation or other abnormalities.

4.2.5 The management of Hernia

Conservative treatment includes lifestyle changes to alleviate symptoms of hiatal hernia; losing weight, taking antacids, eating small meals that pass easily, through the esophagus, not reclining for 3 to 4 hours after eating, elevating the head of the bed 6 to 12 inches to prevent reflux, and avoiding bedtime snacks, spicy foods, alcohol, caffeine, and smoking.



Surgery is done for symptomatic hiatal hernia when GERD, strangulation, or obstruction is present. Fundoplication, in which the stomach fundus is wrapped around the lower part

of the esophagus, is the most common surgical procedure performed

Figure 4.3 Hiatal hernia repair. Nissen fundoplication wraps the stomach fundus around the esophagus and then sutures it onto itself to hold it in place.

4.2.6. Complications

A paraesophageal hernia is rarer but serious as part of the stomach squeezes through the hiatus and is at risk for strangulation (blood supply is cut off).

4.2.7. Associate nurse decision making

In the hospital, the associate nurse will perform tasks that are delegated by registered nurses. The primary focus of care for hiatal hernia disease is educating patients. The teaching guide will include detail the following: The patient is taught lifestyle interventions to reduce the symptoms of hiatal hernia. If the patient undergoes surgery, general postoperative nursing care is provided. In addition,

following fundoplication, patients are assessed for dysphagia during their first postoperative meal. If dysphagia occurs, the physician should be notified because the repair may be too tight, causing obstruction of the passage of food.

Self-assessment 4.2

- 1) Explain the types of hiatal hernia
- 2) What are other diseases that can mimic the signs and symptoms of hiatal hernia?

End Unit assessment 4

- 1) How should the nurse teach the patient with a hiatal hernia or GERD to control symptoms?
 - a) Drink 295 to 355ml of water with each meal.
 - b) Space six small meals a day between breakfast and bedtime.
 - c) Sleep with the head of the bed elevated on 4- to 6-inch blocks
 - d) Perform daily exercises of toe-touching, sit-ups, and weight lifting.
- 2) The patient calls the clinic and describes a bump at the site of a previous incision that disappears when he lies down. The nurse suspects that this is which type of hernia (select all that apply)?
 - a) Ventral
 - b) Inguinal
 - c) Femoral
 - d) Reducible
 - e) Incarcerated
 - f) Strangulated

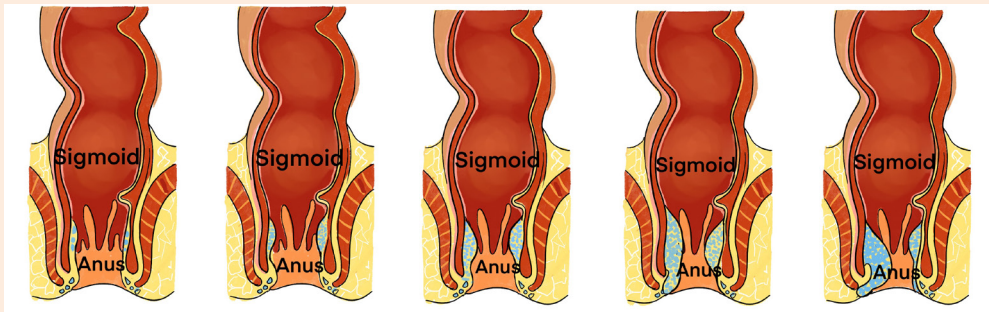
- 3) The patient asks the nurse why she needs to have surgery for a femoral, strangulated hernia. What is the best explanation the nurse can give the patient?
 - a) The surgery will relieve her constipation.
 - b) The abnormal hernia must be replaced into the abdomen.
 - c) The surgery is needed to allow intestinal flow and prevent necrosis.
 - d) The hernia is because the umbilical opening did not close after birth as it should have.
- 4) What are the most frequent symptoms of abdominal Hernia?
- 5) What are the diagnostic measures of hiatal hernia?
- 6) What are the do's and don'ts after inguinal hernia surgery?

Key Unit competence

Take appropriate decision on Hemorrhoids conditions.

Introductory activity 5.0

The images below from A to E illustrate the structures of the cross section of sigmoid and anus. Observe them and respond to the attached questions.



- 1) What are the physiological changes would reflect these changes in the intestines?
- 2) What are the manifestations of such abnormalities in the human body?
- 3) How can health personnel identify or notice these abnormalities?
- 4) How can these abnormalities be corrected?

5.1. Description of Hemorrhoids

Learning Activity 5.1

N.A is a 37-year-old pregnant woman consults the hospital with pain in the rectum during and after passing stools. She said that he saw blood on the toilet paper that she used. She also mentioned that she has been having hard stool since some weeks and itching. The medical doctor put the patient on the left lateral decubitus with the N. A's knees flexed toward the chest, he inspected the anus and performed anal digital examination. A bulging mucosa was observed during inspection and palpated confirming external hemorrhoids.

Questions related to the case study

- 1) What is the medical history of N.A described in the case study?
- 2) Do you think that this history has something to do with the haemorrhoids? Explain your response.
- 3) Describe the signs and symptoms presented in the case study.

5.1.1. Definition of Hemorrhoids

Hemorrhoids are a very common anorectal condition defined as the symptomatic enlargement and distal displacement of the normal anal cushions.

5.1.2. Causes and pathophysiology of hemorrhoids

The exact pathophysiology of hemorrhoidal development is poorly understood. For years the theory of varicose veins, which postulated that hemorrhoids were caused by varicose veins in the anal canal, had been popular but now it is obsolete because hemorrhoids and anorectal varices are proven to be distinct entities. Today, the theory of sliding anal canal lining is widely accepted. This proposes that hemorrhoids develop when the supporting tissues of the anal cushions disintegrate or deteriorate. Hemorrhoids are therefore the pathological term to describe the abnormal downward displacement of the anal cushions causing venous dilatation and increase in pressure in the veins.

Some of the risk factors of hemorrhoids include pregnancy, prolonged sitting or standing position, obesity and chronic constipation. Portal hypertension related to liver disease may also be a factor.

5.1.3 Signs and symptoms of Hemorrhoids

Internal hemorrhoids (Fig 5.1) are usually not painful unless they prolapse. They may bleed during bowel movements. External hemorrhoids (Fig 5.1) cause itching and pain when inflamed and filled with blood (thrombosed). Inflammation and edema occur with thrombosis, causing severe pain and possibly infarction of the skin and mucosa over the hemorrhoid.

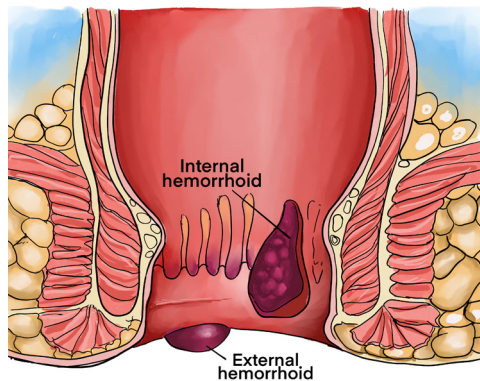


Figure 5.1 Internal and external hemorrhoids

5.1.4 Diagnostic measures

The Hemorrhoids can be diagnosed through a complete history, physical examination; (lubricated finger, gently inserted into the anal canal while asking the

patient to bear down the resting tone of the anal canal). Internal hemorrhoids are generally not palpable on digital examination, anoscopy is performed. Hemorrhoidal bundles will appear as bulging mucosa and anoderm within the open portion of the anoscope. Sigmoidoscopy and colonoscopy can also be used. A complete blood cell (CBC) count may be useful as a marker for infection. Anemia due to hemorrhoidal bleeding is possible.

Self-assessment 5.1

- 1) Briefly explain the pathophysiology of Hemorrhoids?
- 2) Identify other diseases that would mimic the symptoms of Hemorrhoids?

5.2. The management of Hemorrhoids

Learning Activity 5.2

...Continuation of N.A case study

After physical exam, the medical doctor confirmed that Madam N.A is suffering from Hemorrhoids. Regarding the treatment, Mr. S.D has received anti-inflammatory drugs and advice on how to change her lifestyle.

Questions related to the case study.

- 1) What is the surgical treatment plan adopted by the medical doctor for this patient?
- 2) In group, discuss the different medication prescribed to this patient.
- 3) List potential complications which may happen to Madam N.A.

5.2.1. The treatment plan of Hemorrhoids

Treatment is aimed at preventing constipation, avoiding straining during defecation, maintaining good personal hygiene, and making lifestyle changes to relieve hemorrhoid symptoms and discomfort. Lifestyle modification use of anti-inflammatory and surgery are the treatment of hemorrhoids

5.2.2. Associate nurse decision making

In the hospital, the associate nurse will perform tasks that are delegated by registered nurses. The primary focus of care for haemorrhoids disease is educating patients. Encourage patient and caregiver to share concerns about lifestyle.

5.2.3. Complications of Hemorrhoids

The most common and serious complications of haemorrhoids include perianal thrombosis and incarcerated prolapsed internal haemorrhoids with subsequent thrombosis. They are characterised by severe pain in the perianal region possibly with bleeding. In a short history of the perianal thrombosis, acute surgical incision or excision is indicated, which can result in rapid relief of the painful symptoms

Self-assessment 5.2

Mr. K.M a patient on your department unit, has a Hemorrhoids. His wife runs to the nursing station and says that you need to help her husband, he is in pain.

- 1) What additional data would you gather to confirm the statement of her wife?
- 2) What emotional support would you offer to Mrs. SM?

End Unit assessment 5

- 1) Following a hemorrhoidectomy, what should the nurse advise the patient to do?
 - a) Use daily laxatives to facilitate bowel emptying.
 - b) Use ice packs to the perineum to prevent swelling.
 - c) Avoid having a bowel movement for several days until healing occurs.
 - d) Take warm sitz baths several times a day to promote comfort and cleaning.
- 2) A patient is scheduled for a hemorrhoidectomy at an ambulatory day-surgery center. An advantage of performing surgery at an ambulatory center is a decreased need for
 - a) laboratory tests and perioperative medications.
 - b) preoperative and postoperative teaching by the nurse.
 - c) psychologic support to alleviate fears of pain and discomfort.
 - d) preoperative nursing assessment related to possible risks and complications.
- 3) Apart from digital examination, what are other diagnostic tests indicated in the case of hemorrhoids?

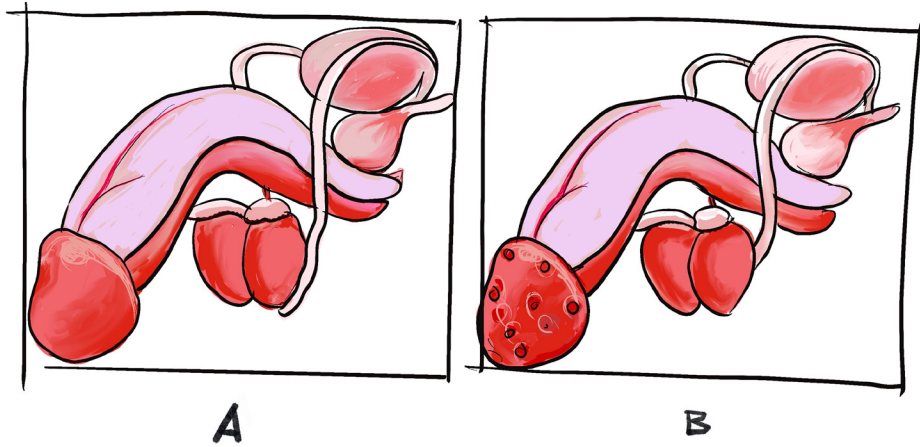
- 4) Changing life style is one way to prevent and treat hemorrhoids. What are the lifestyle modifications would you recommend a patient with haemorrhoids?
- 5) What is the role of medications in the treatment of haemorrhoids?The goals of pharmacotherapy are to reduce pain and constipation in patients with haemorrhoids.
- 6) What is the role of pregnancy in the aetiology of haemorrhoids?Pregnancy clearly predisposes women to symptoms from haemorrhoids, although the aetiology is unknown. Notably, most patients revert to their previously asymptomatic state after delivery. The relationship between pregnancy and haemorrhoids lends credence to hormonal changes or direct pressure as the culprit.
- 7) What is the role of blood studies in the workup of hemorrhoids? A complete blood cell (CBC) count may be useful as a marker for infection. Anemia due to hemorrhoidal bleeding is possible
- 8) What is the role of colonoscopy in the workup of hemorrhoids? Colonoscopy, virtual colonoscopy, and barium enema are reserved for cases of bleeding without an identified anal source.

Key Unit competence

Take appropriate decision on balanitis and balanoposthitis

Introductory activity 6.0

The Image A and B illustrate the structures of male reproductive organs. Observe them and respond to the attached questions.



- 1) Which one of these two figures (A&B) would reflect the normal or abnormal structure of the male reproductive organ in humans?
- 2) What explanations can you give to justify the abnormal structure of the male reproductive organ you have found?
- 3) What do you think can cause the modifications that you have observed?
- 4) What are the manifestations of such abnormalities in the human body?
- 5) How can health personnel identify or notice these abnormalities of male reproductive organ in humans?

6.1. Description of Balanitis and Balanoposthitis

Learning Activity 6.1

You are at health center on day duty in consultation, you receive Mr. K C., a 26 year's old uncircumcised male patient. He was complaining of urethral discharge and painful urination. During history taking he reveals you that he had the same signs and symptoms, 6 months ago and bought some drugs from the pharmacy and symptoms disappeared. Once asked if he had sex in previous time, he reveals you that he had it twice before developing the signs and symptoms and he confirms that he did not told his girlfriend. During the physical exam of external genitalia, you notice that the glans and the prepuce are inflamed, reddened, with foul smell white discharge under the foreskin. At this stage, different diseases are presumed including gonorrhea, balanitis, syphilis and candida. Urinalysis, urethral opening swab and blood test were requested for better diagnosis. Finally, the exams revealed a balanitis/ balanoposthitis caused by gonorrhea. After confirming balanitis/ balanoposthitis. The treatment of gonorrhea was given and KC was advised to have circumcision and to bring her girl friend to get treatment as well.

Questions related to the case study:

- 1) What are possible risk factors which might probably exposed K.C to this problem?
- 2) Identify the signs and symptoms as described in the case study
- 3) Which statement by the patient indicates the most likely cause of the recurrence of his infection?
 - a) "I took the Vibramycin twice a day for a week."
 - b) "I haven't told my girlfriend about my infection yet."
 - c) "I had a couple of beers while I was taking the medication."
 - d) "I ve only had sexual intercourse once since my medication"
- 4) Why blood tests were included in the diagnostic tests to find the diagnosis of K.

6.1.1. Definition and the Balanitis and Balanoposthitis

Balanitis is often confused with two similar conditions: phimosis, balanoposthitis and prosthitis. All these conditions affect the penis. However, each condition affects a different part of the penis.

- Phimosis is a condition that makes it difficult to retract the foreskin.

- Balanitis is inflammation of the head (glans) of the penis.
- Balanoposthitis is inflammation of both the penis head (glans) and the foreskin.
- Prosthitis is the inflammation of the prepuce

6.1.2. Causes and pathophysiology of Balanitis and Balanoposthitis

Balanitis and Balanoposthitis are mostly caused by poor hygiene in uncircumcised men. Other causes may include:

- Sexually transmitted diseases/infections(STDs/STIs) such as Gonorrhea, chlamydia, trichomonas vaginalis, mycoplasma genitalium, genital herpes, human papilloma virus(HPV), syphilis
- Genital yeast infection (candidiasis).
- Diabetes
- Scabies (tiny burrowing parasite) infection.
- Skin conditions that cause itchy, dry, scaly skin (ex. In psoriasis and eczema diseases conditions).
- Reactive arthritis, a type of arthritis that develops in response to an infection somewhere in the body
- Reactive arthritis, a type of arthritis that develops in response to an infection somewhere in the body.

Beside poor hygiene among uncircumcised men, **other predisposing factor** include: over-the-counter (OTC) medications, and no- retraction of the foreskin.

Balanitis can be classified under different types

- **Balanitis (also called Zoon's balanitis):**
 - This is the main type of balanitis,
 - usually affects uncircumcised, middle-aged men
 - the head of penis is inflamed, painful, and reddened
- **Circinate balanitis:**
 - This is the type of Balanitis which occurs as a result of reactive arthritis, (an arthritis that develops in response to an infection in the body).
 - Inflammation, redness, pain, and small lesions (sores) on the head of the penis are present
- **Pseudoepitheliomatous keratotic and micaceous balanitis:**
 - very rare form of balanitis
 - It mostly affects men over 60
 - scaly warts on the glans is present

6.1.3 Signs and symptoms of Balanitis and Balanoposthitis

Generally, signs and symptoms of balanitis may appear suddenly or gradually. They can include:

- Swelling
- Pain and irritation on the glans (head of the penis).
- Redness or red patches on the penis.
- Itching under the foreskin.
- Areas of shiny or white skin on the penis.
- White discharge (smegma) under the foreskin
- Foul smell.
- Painful urination.
- Sores or lesions on the glans (rare and specific to **Pseudoepitheliomatous keratotic and micaceous balanitis**)

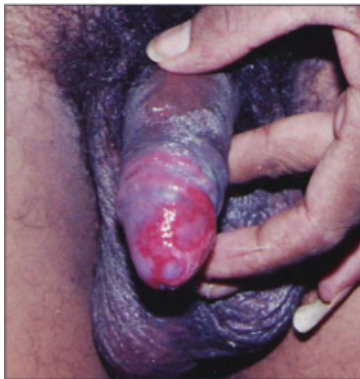

Figure 6.1. Example of Herpetic balanitis

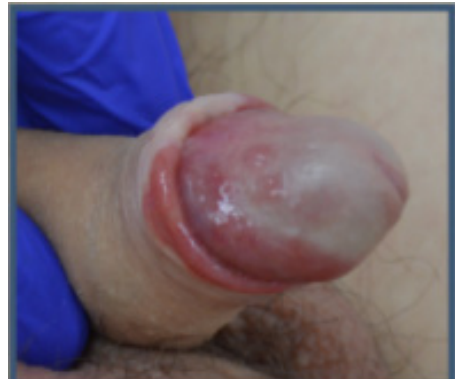

Figure 6.2. Example of Balanoposthitis

6.1.4 Diagnostic measures of Balanitis and Balanoposthitis

The Balanitis and Balanoposthitis can be diagnosed through a complete history, physical examination as well as some diagnostic test to determine the underlying cause like infection

- Urinalysis
- urethral opening swab
- blood test: glycaemia (to exclude Diabetes mellitus), full blood count (to determine the type of infection)

NB: In people with recurrent balanitis and balanoposthitis, HIV test is advisable

Self-assessment 6.1

- 1) What are the signs and symptoms of balanitis and balanoposthitis?
- 2) Briefly explain the pathophysiology of Balanoposthitis?
- 3) All types of balanitis share almost the same signs and symptoms. What is the specific sign and particular sign for circinate **balanitis**?
- 4) List the treatment goals of Balanitis and Balanoposthitis

6.2.1 The treatment of Balanitis and Balanoposthitis

The treatment and management of balanitis depends on the underlying cause and contributing factors. Whatever the treatment plan, the goal of treatment is to:

- Minimize sexual dysfunction
- Minimize urinary dysfunction
- Exclude penile cancer
- Treat premalignant disease
- Diagnose and treat sexually transmitted disease.

Depending on the cause, the treatments can include:

- **Antibiotics:** If a sexually transmitted infection (STI) is confirmed to be the cause of balanitis, the antibiotics will be prescribed. The antibiotic will also depend on the type of infection (Gonorrhoea, chlamydia, trichomonas vaginalis, mycoplasma genitalium, genital herpes, human papilloma virus(HPV), syphilis)
- **Circumcision:** is a surgical procedure in which the foreskin covering the penis is surgically removed. Circumcision is recommended in case of recurring symptoms of balanitis in uncircumcised
- **Antifungal creams:** is prescribed if the yeast infection is the underlying cause of balanitis. Antifungal like clotrimazole will be applied the glans (head of the penis) and foreskin as prescribed.
- **Diabetes management:** If you have diabetes, your provider will show you how to manage the condition.
- **Improved hygiene:** this consist of washing and drying under the penis's foreskin (glands) often to reduce the risk of reoccurrence of balanitis.

6.2.2. Evolution and complications of Balanitis and Balanoposthitis

Untreated balanoposthitis does not usually cause serious complication except when its underlying cause are cancerous origin.

Generally untreated inflammation of the glans of the penis (balanitis) is frequently associated with a degree of the inflammation of the foreskin (posthitis), a situation which can lead to the following:

- **Phimosis:** retraction of the penis's foreskin. The foreskin may swell, cause pain, and blockage during urinating. The swelling is typically described as balloon-like swelling or 'ballooning').
- **Paraphimotic:** a surgical condition whereby the penis' foreskin becomes trapped behind the head of the penis, and cannot be pulled over the head to its normal position. This is typically very painful and considered a medical emergency. It must be treated as soon as possible, otherwise the blood flow to the glans may be restricted, and complete circumcision will need to be carried out in advanced cases.
- **Structure of urethral meatus:** the scarring around the opening of the waterpipe, due to chronic inflammatory changes, can lead to the narrowing of the water hole.

End Unit assessment 6

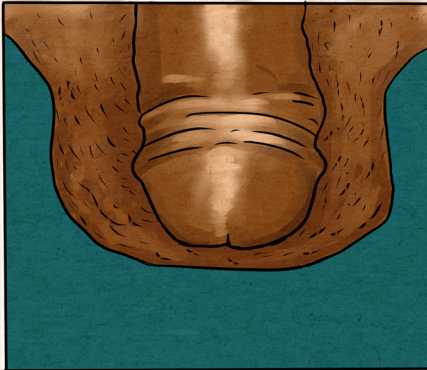- 1) An abnormal finding noted during physical assessment of the male reproductive system is
 - a) Descended testes.
 - b) Symmetric scrotum.
 - c) Slight swollen and reddish glans of penis
 - d) The glans covered with prepuce.
- 2) List the complications of Balanitis and Balanoposthitis
- 3) What are the preventive measures for Balanitis/ Balanoposthitis?
- 4) How clotrimazole cream for balanitis is used?
- 5) What are the treatment modalities of Balanitis/ Balanoposthitis?

Key Unit competence

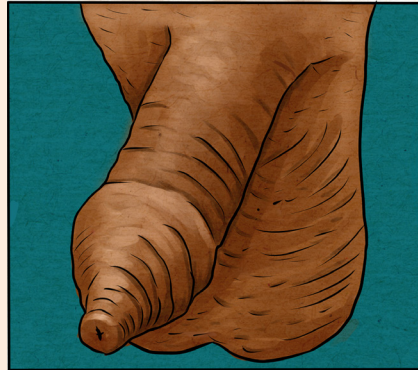Take appropriate decision on phimosis and paraphimosis conditions.

Introductory activity 7.0


The Image A, B, C and D illustrate the structures of male reproductive organs. Observe them and respond to the attached questions



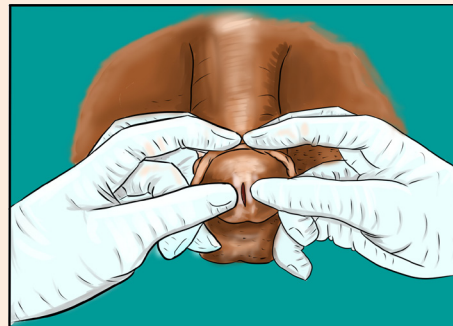
A



B



C



D

- 1) What do you think on the figure A, B, C&D?
- 2) What are your observations on figures (A, B, C&D) would reflect the abnormal structure of the male reproductive organ in humans?
- 3) What do you see in image B and C?
- 4) What is the difference between A and C?
- 5) What do you think about that someone is doing in image D?

7.1. Description of Phimosis and Paraphimosis

Learning Activity 7.1

Miss D.K is associate nurse at one health facility in rural area of Rwanda. During her night duty, she received Mr. M G, a 26 year's old uncircumcised male patient. He was complaining of foreskin scratching, painful urination and painful erections. During history taking he reveals to nurse that he had inability to pulldown the foreskin since birth and the same signs and symptom since 6 months ago. The nurse in charge of consultation examined him and a diagnosis of phimosis was made and a rendez vous for circumcision was fixed on the next 2 days. Arriving at home, he wanted to take shower before sleeping. While performed genital hygiene, he tried to retract his prepuce for more visualization but he failed to retract it back. Immediately he started to feel severe penile pain and inability to pass urine as he felt something like a barrier to pass the urine. During the physical exam of external genitalia, Nurse noticed that the glans and the prepuce are inflamed, reddened. He is glans appears enlarged and congested, with a collar of swollen foreskin around the coronal sulcus. At this stage, the final diagnosis was made: patient was suffering from phimosis complicated into paraphimosis. Finally, Nurse attempted the manual reduction and failed. The decision for surgical treatment was made: Performance of sterile circumscision under local anesthesia (emergency dorsal slit) and prescription of painkiller was done.

Questions related to the case study:

- 1) Basing on the case scenario, what are the causes and possible risk factors which might probably exposed MG to this problem?
- 2) Identify the signs and symptoms Mr. MG presented at health facility
- 3) Why lab tests were not included in the diagnostic tests to find the diagnosis of MG?
- 4) How nurse diagnosed the condition of Mr. MG?
- 5) Which treatment did they provide to Mr. MG?

7.1.1 Definition and the Phimosis and Paraphimosis

Phimosis and paraphimosis are conditions that occur among uncircumcised male clients when the opening of the foreskin is constricted. All these conditions affect the penis foreskin.

Phimosis: is defined as the inability to retract the skin (foreskin or prepuce) covering the head (glans) of the penis and leading to a tightness or constriction of the foreskin around the head of the penis, making retraction difficult. Phimosis may appear as a tight ring or “rubber band” of foreskin around the tip of the penis, preventing full retraction.

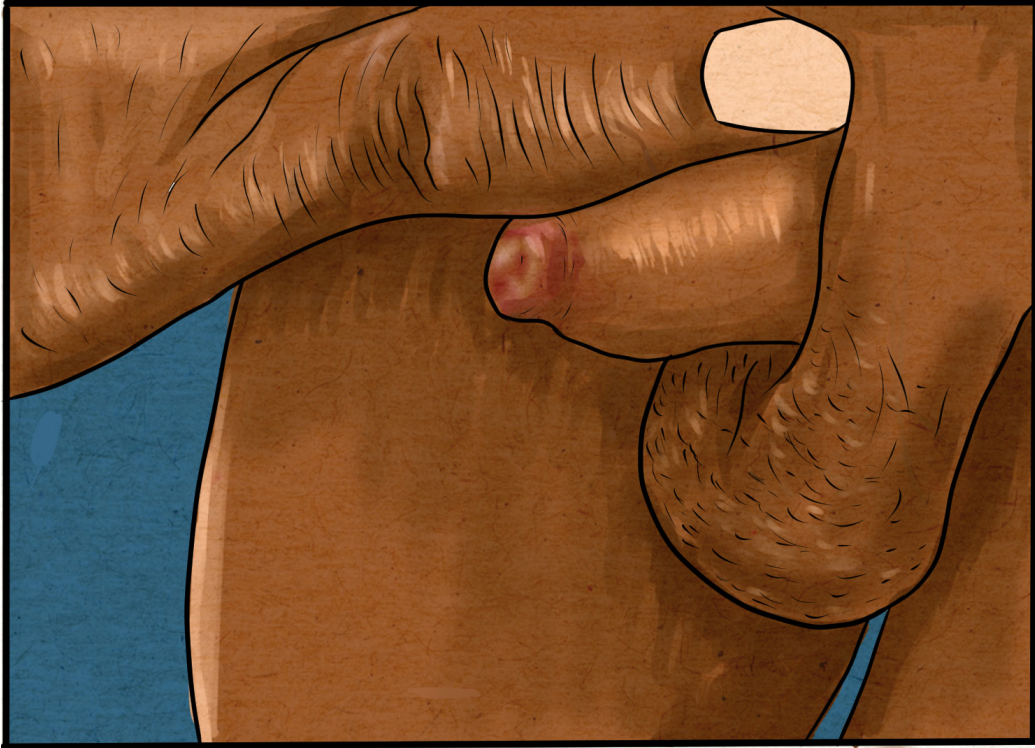


Figure 7.1.: Patient with Phimosis

Physiologic VS Pathologic Phimosis

Depending on the situation, this condition may be considered either physiologic or pathologic. Physiologic, or congenital, phimosis is a normal condition of the newborn male and in children younger than 3 years of age, and may be a normal finding up until the age of puberty while acquired (pathologic) phimosis is most seen in post pubertal males, or in patients in whom scarring has developed from chronic infection and inflammation (balanoposthitis), or as a result of repeated forced retraction of congenital phimosis.

Smegma: is a collection of skin cells from the glans penis and inner foreskin that is often noted with retraction of the foreskin. This natural skin shedding helps to separate the foreskin from the head of the penis. Smegma may appear as white pearls underneath the skin, which can easily be washed off once the foreskin is retracted.

Paraphimosis: is a strangulation of the glans penis from an inability to replace the retracted foreskin. It is a urologic emergency, occurring in uncircumcised males, in which the foreskin becomes trapped behind the corona and forms a tight band of constricting tissue.




Figure 7.2 : Image of showing case of paraphimosis

7.1.2 Causes and risks factors of Phimosis and Paraphimosis

Phimosis is a tightness or constriction of the foreskin around the head of the penis, making retraction difficult, is caused by edema or inflammation of the foreskin, usually associated with poor hygiene techniques that allow bacterial and yeast organisms to become trapped under the foreskin. Congenital phimosis is expected in children younger than 3 years of age, and may be a normal finding up until the age of puberty. These phimotic conditions often are caused by a congenitally small foreskin; however, chronic inflammation at the glans penis and prepuce secondary to poor hygiene or infection also are etiologic factors.

Beside poor hygiene in young children others various reasons may also contribute to development of phimosis including:

- Skin conditions such as eczema, psoriasis, lichen planus and lichen sclerosus. When it affects the penis, lichen sclerosus is known as penile lichen sclerosus or balanitis xerotic obliterans (BXO).
- Preputial adhesions, or scar tissue, that keep the foreskin attached to the tip (glans) of your penis.
- Injuries.
- Infections, including sexually transmitted infections (STIs).

The cause of paraphimosis is **most often iatrogenic**. The condition is frequently occurring after penile examination, urethral catheterization or cystoscopy. Paraphimosis typically occurs after Foley catheter placement. Rare causes of paraphimosis include self-inflicted injury to the penis (such as piercing a penile ring into the glans) and paraphimosis secondary to penile erections

7.1.3 Pathophysiology and Types of Phimosis and Paraphimosis

When the foreskin becomes trapped behind the corona for a prolonged time, it may form a tight, constricting band of tissue. This circumferential ring of tissue can impair the blood and lymphatic flow to and from the glans and prepuce. As a result of penile ischemia and vascular engorgement, the glans and prepuce may become swollen and edematous. If left untreated, penile gangrene and auto amputation may follow in days or weeks. Phimosis is divided into two forms: **physiologic and pathologic phimosis**.

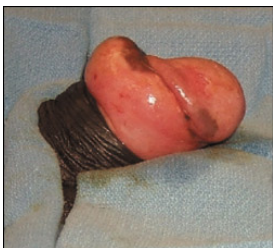Physiologic phimosis: Children are born with tight foreskin at birth and separation occurs naturally over time. Phimosis is normal for the uncircumcised infant/child and usually resolves around 5-7 years of age, however the child may be older.

Pathologic phimosis: Phimosis that occurs due to scarring, infection or inflammation. Forceful foreskin retraction can lead to bleeding, scarring, and psychological trauma for the child and parent. If there is ballooning of the foreskin during urination, difficulty with urination, or infection, then treatment may be warranted.

7.1.4 Signs and Symptoms of Phimosis and Paraphimosis

Clients with phimosis report pain with erection and intercourse and difficulty cleaning under the foreskin.

Clients with paraphimosis often presents with penile pain. However, pain may not always be present. The glans appears enlarged and congested, with a collar of swollen foreskin around the coronal sulcus. If the condition continues, severe edema and urinary retention may occur. A tight, constricting band of tissue appears immediately behind the head of the penis as shown in the figure below.



The rest of the penile shaft is flaccid and unremarkable. Infants and children with paraphimosis may present with obstructive voiding symptoms and, when severe, acute urinary obstruction may be developed.

7.1.5. Adequate diagnosis of Phimosis and Paraphimosis

Diagnosis is typically on clinical findings identified in a wide variety of age groups from newborn to adult. In physiologic phimosis, benign (non-life threatening) conditions may occur that are common in uncircumcised males, including; cysts related to smegma production/trapping and transient painless ballooning of the foreskin during urination. These are considered normal variations that usually resolve with daily gentle manual retraction.

The physical examination should focus on the penis, urethral catheter (if present) and scrotum. The penis should be inspected for the presence of foreskin, the color of the glans, the degree of constriction around the penile corona and turgor of the prepuce. Absence of foreskin excludes the diagnosis of paraphimosis. **A pink or salmon hue** to the glans indicates a good blood supply.

Self-assessment 7.1

- 1) What are the signs and symptoms of paraphimosis?
- 2) Briefly explain the pathophysiology of the paraphimosis?
- 3) **Differentiate** Physiologic phimosis **from** **pathologic phimosis**
- 4) **List the risks factors associated to paraphimosis?**

7.1.6 Treatment plan of Phimosis and Paraphimosis

Treatments for phimosis and paraphimosis vary depending on the child and severity of phimosis. It involves reducing the penile edema and restoring the prepuce to its original position and may include: gentle daily manual retraction, topical corticosteroid ointment and application or circumcision. Several noninvasive or minimally invasive methods are used to reduce the penile swelling, but due to extreme pain patients may require a penile nerve block or topical analgesic or oral narcotics before penile manipulation.

- **Manual reduction of phimosis and Paraphimosis:**

The goal of treatment is to return the foreskin to its natural position over the glans penis through **manual reduction**. Manual pressure may reduce edema. A gloved hand is circled around the distal penis to apply circumferential pressure and disperse the edema. One strategy involves pushing the glans back through the prepuce by applying constant thumb pressure while the index fingers pull the prepuce over the glans. Ice and/or hand compression on the foreskin, glans, and penis may be done before this technique to reduce edema. Topical corticosteroid cream applied two or three times daily to the exterior and interior of the tip of the foreskin may also be effective.

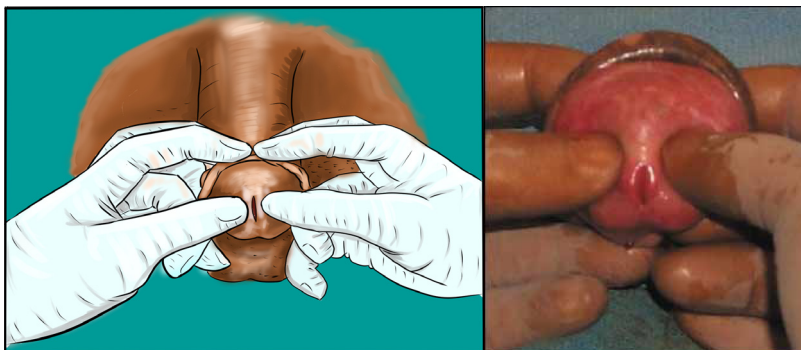


Figure 7.3: Manual reduction of phimosis and paraphimosis

Ice packs are also useful in reducing swelling of the penis and prepuce. The penis is first wrapped in plastic, with ice packs applied intermittently until the swelling subsides. To reduce edema, a compressive elastic dressing is then wrapped circumferentially around the penis from the glans to the base. This dressing should be left in place for five to seven minutes, and the penis should be checked periodically to monitor the resolution of swelling. Once the swelling has subsided, the wrap should be removed.

- **Pharmacologic therapy**

Injection of hyaluronidase into the edematous prepuce is effective in resolving edema and allowing the foreskin to be easily reduced. Degradation of hyaluronic acid by hyaluronidase enhances diffusion of trapped fluid between the tissue planes to decrease the preputial swelling. Hyaluronidase is well suited for use in infants and children.

Granulated sugar has shown to be effective in the treatment of paraphimosis based on the principle of fluid transfer occurring through osmotic gradient. Granulated sugar is generously spread on the surface of the edematous prepuce and glans. The hypotonic fluid from the edematous prepuce travels down the osmotic gradient into the sugar, reducing the swelling and allowing for manual reduction. Both of the procedures mentioned here should be performed by a physician experienced in these techniques

- **Minimally invasive therapy**

The “**puncture**” technique is a minimally invasive therapy in which a hypodermic needle is used to directly puncture the edematous prepuce. Puncture sites permit safe and effective evacuation of the trapped fluid. External drainage of the trapped fluid allows for manual reduction of paraphimosis.

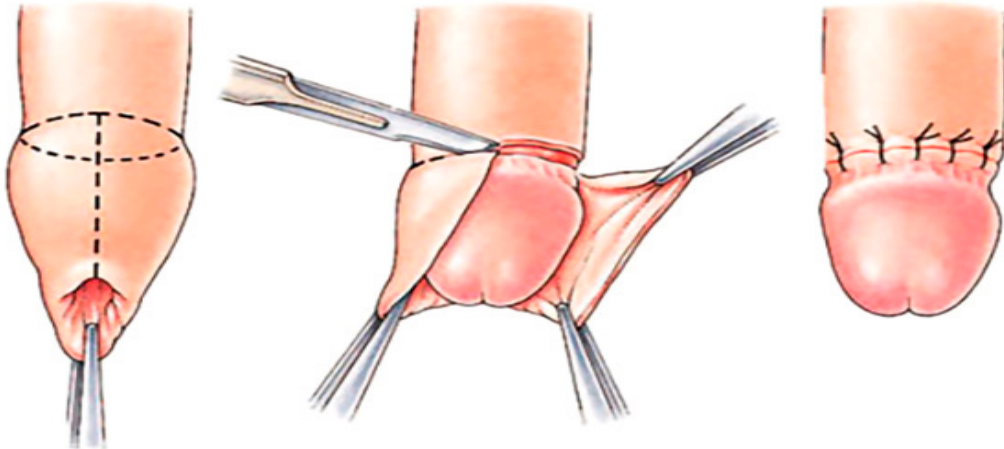
Blood aspiration of the tourniqueted penis may be attempted. The base of the penis is temporarily tied off with a rubber tourniquet. An 18-gauge needle is inserted into the penis, and corporal blood is aspirated to reduce penile swelling. These techniques should only be performed by a physician experienced in the procedures.

N.B: All of these techniques are geared toward reducing the swelling so that manual reduction can be performed.

After the preputial swelling has subsided, paraphimosis is reduced. To reduce the prepuce, the thumbs of both hands are placed on the glans and the fingers wrap behind the prepuce. A gentle but steady and forceful pressure is applied to the glans with the thumbs, and counter traction is applied to the foreskin with the fingers as the prepuce is pulled down. When performed properly, the constricting band of tissue should come down distal to the glans with the prepuce.

- **Surgical therapy**

Severe constricting band of tissue precludes all forms of conservative or minimally invasive therapy, an emergency circumcision dorsal slit type is recommended to relieve these conditions permanently. This procedure should be performed with the use of a local anesthetic by a physician or a trained health care personnel experienced with the technique. Circumcision, a definitive therapy, should be performed at a later date to prevent recurrent episodes, regardless of the method of reduction used.



7.1.7 Evolution and complications of Phimosis and Paraphimosis

The prognosis for phimosis is usually very good. A small amount of bleeding can occur as the skin is retracted but long term negative outcomes are very rare. Complications of phimosis include balanitis, posthitis, paraphimosis, voiding dysfunction, painful erection and penile carcinoma. Patients may present with complaints of erythema, itching, discharge, or pain with sexual intercourse.

The prognosis for paraphimosis depends on the speed of diagnosis and reduction constricting band of tissue. With prompt treatment, the outlook is excellent. But without effective or delayed treatment, complications that can occur with paraphimosis will range from mild to severe and life threatening condition. These include pain, infection, and inflammation of the glans penis. If the condition is not relieved in a sufficiently prompt timeframe, the distal penis can become ischemic or necrotic. When this happens, paraphimosis can result in: a severe infection, damage to the tip of the penis, gangrene, or tissue death, resulting in the loss of the tip of the penis.

End Unit assessment 7

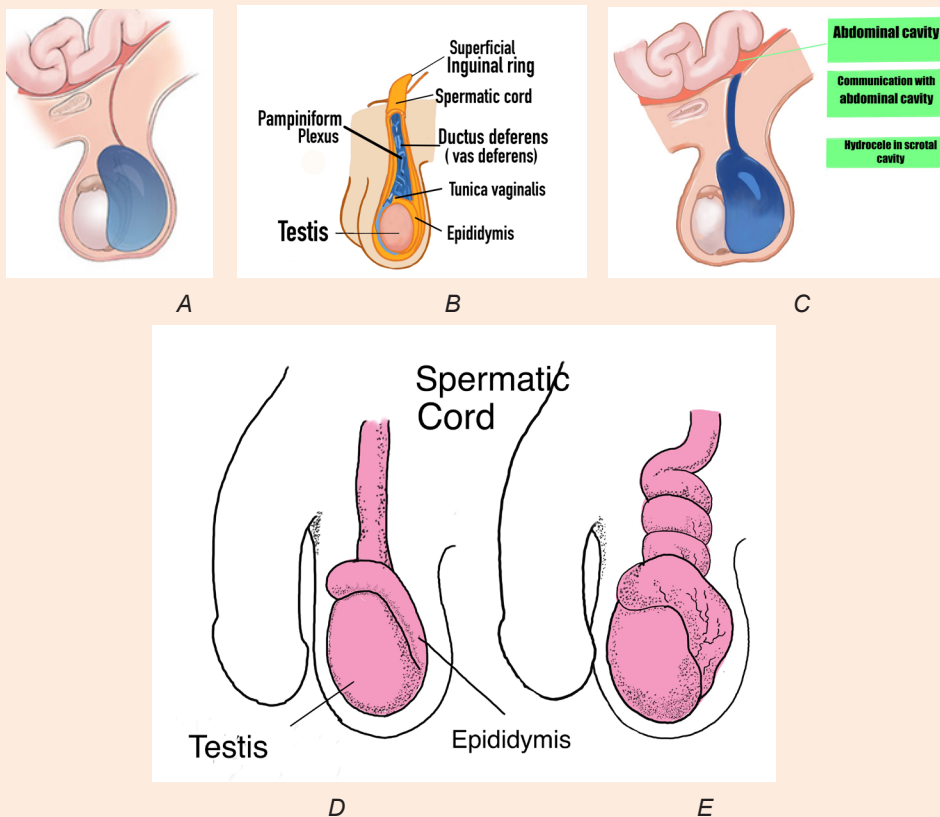
- 1) Which patient is at the greatest risk for developing Paraphimosis condition?
 - a) Circumcised Patient with chronic sexual transmitted diseases
 - b) Patient with urinary tract infection
 - c) A 17-year-old man with pre-existence congenital phimosis
 - d) A 65-year-old circumcised patient with urinary incontinence
- 2) What is the most important cause of the paraphimosis among the following?
 - a) Skin conditions such as eczema, psoriasis and lichen planus
 - b) Iatrogenic cause like urethral catheterization or cystoscopy.
 - c) Injury to genital organ
 - d) Multiple Sexual activity
 - e) for circumcised men
- 3) List the 4 components of treatment plan for phimosis and paraphimosis
- 4) Explain the importance of pain killer before manual reduction of paraphimosis.
- 5) Explain the goal of manual reduction of phimosis and paraphimosis.
- 6) What can you do to reduce edema if you are called to care for patient with paraphimosis?
- 7) When surgical therapy will be decided in case of paraphimosis?
- 8) What can be done to prevent complications to paraphimosis?
- 9) List 4 complications of phimosis and paraphimosis?

Key Unit competence

Take appropriate decision on Hydrocele and Testicular torsion.

Introductory activity 8.0

The image A, C and c illustrate the structures of testicle. Observe image A, B, C, D and E and answer the questions below.



Source: <https://www.slideshare.net/MachitjaTlali/hydrocele-by-tlali>

Draw the image without labels, and make image D in the black context

- 1) Which one of these three images (A, B, C, D) would reflect the normal structure of testicle?
- 2) What is the difference between image A and B?
- 3) What is the difference between image A and C?
- 4) What is the difference between image D and E?
- 5) How can these abnormalities be corrected?

8.1. Description of hydrocele

Learning Activity 8.1

H.K is a 5 years old boy was referred to the surgical OPD for urologist review on 20.5.2022 with swelling of right scrotum since 5 months. The mother complained of swelling of right scrotum, which increased in size gradually. There was mild pain when the swelling started. There was no history of fever or trauma when it started. The physician performed trans-illumination test which become positive and hydrocele was confirmed. The patient was scheduled for surgery to drain the fluid accumulated in the scrotum under local anaesthesia using needle and syringe.

Questions related to the case study

- 1) Identify the biography of the patient described in the case study.
- 2) What are the signs and symptoms described in the case study?
- 3) What is the probable surgical diagnosis of this H.K?
- 4) Which test performed to confirm surgical diagnosis described in the case study?

8.1.1. Definition of hydrocele

A hydrocele is a non-tender, fluid-filled mass that results from interference with lymphatic drainage of the scrotum and swelling of the tunica vaginalis that surrounds the testis. Hydroceles vary greatly in size. Very large hydroceles are sometimes seen in elderly men and it might have been getting larger over a number of years.

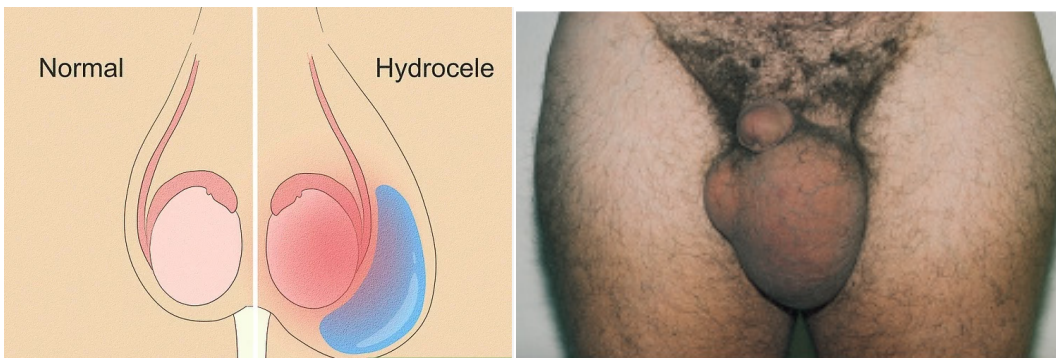


Fig 8.1 Hydrocele illustration

8.1.2. Causes of hydrocele

Most hydroceles occur in adults and are most common in men aged over 40 years. The causes of hydrocele is unknown in most of cases. A few cases of hydroceles occur when something is wrong testicles. For instance, infection, inflammation, injury or tumours involving the testes may cause fluid be accumulated which leads to hydrocele formation.

8.1.3. Types of hydrocele

Communicating hydrocele

In communicating hydrocele the opening does not close and fluid is able to go back between abdominal cavity and scrotal cavity.

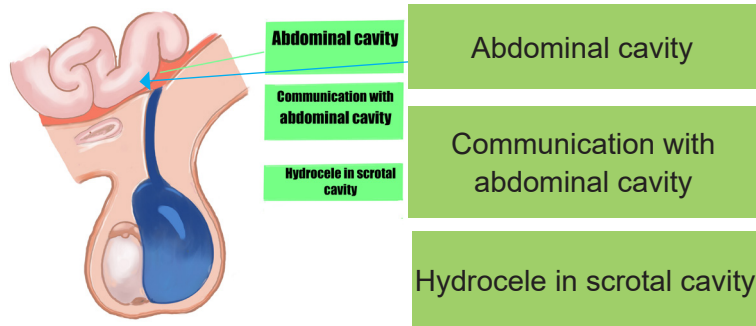
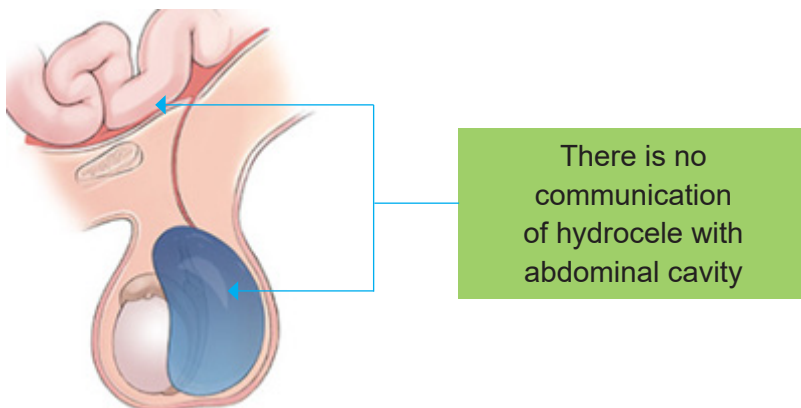


Fig 8.2 Communicating hydrocele.

Non-communicating hydrocele

The open remains closed after the testicle is in the scrotum but there is fluid trapped in the scrotum. This type is mostly found often in new-born and may take up to one to resolve.



8.1.4. Signs and symptoms of hydrocele

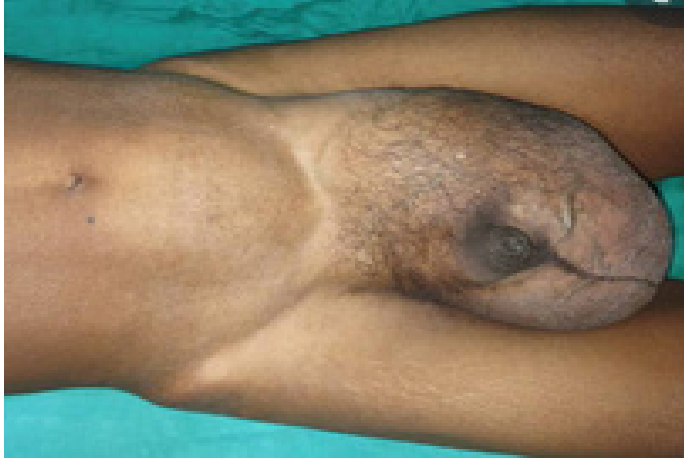

Figure 8.4 Scrotal swelling around the testes.

Non-communicating hydrocele is characterized by a constant swelling.

On the other hand, in communicating hydrocele the swelling comes and goes throughout the course of a day.

Fluid around the testis does not usually cause pain or discomfort.

8.1.5. Diagnosis of hydrocele

Doctor uses the following modalities to diagnose hydrocele:

Doctors usually perform a physical examination for diagnosing Hydrocele. During exam the doctor will not be able to feel the testicle well due to the presence of fluid in the sac. Doctors will also check for tenderness in scrotum and shine a light through the sac. This procedure is called “**trans-illumination**” and it allows the doctor to determine presence of fluid. The scrotum will allow light transmission if fluid is present. It will appear to light up with light passing through it. The light will not shine through the scrotum if the swelling is due to solid mass. The doctor may also perform an ultrasound to check for tumors, hernias or any other cause for swelling of the scrotum.

Ultrasound: This can help to check your testes to make sure if there aren't other underlying causes of hydrocele.

8.1.6. Treatment plan of hydrocele

Two modalities of hydrocele management

- A. Aspiration with needle and syringe
- B. Surgical management (hydrocelectomy)

A. Aspiration with needle and syringe

This procedure can be performed for non-communicating hydrocele once the scrotum become swollen.

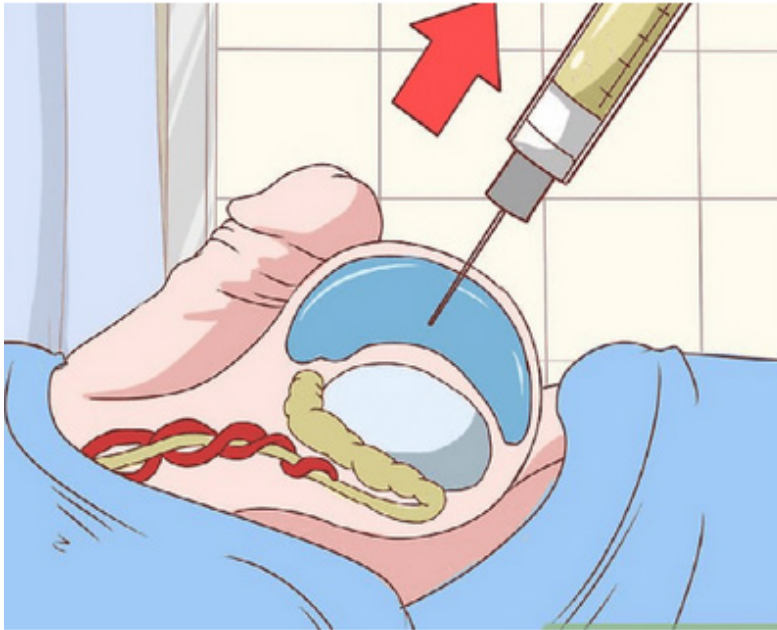


Figure 8.5 : Hydrocele aspiration using needle and syringe

B. Surgical management of hydrocele

Non-communicating hydrocele: Normally resolve on its own over time and do not require surgery. The surgery is required if swelling persists past 12 months of age.

Communicating hydrocele: This types, do not resolve on its own and it requires surgery (hydrocelectomy). The surgery is recommended to decrease the chance of a loop of bowel or abdominal contents getting stuck which could hurt the bowel and the testicle. This surgery is done under anaesthesia and small incision is made in the groin.

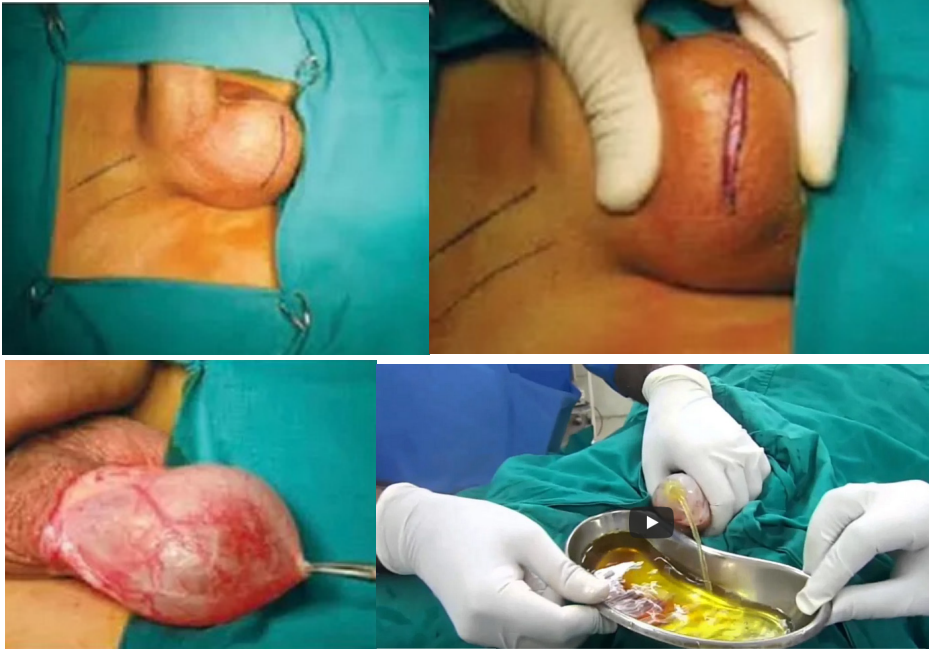

Figure 8.6 : Hydrocelectomy procedure

8.1.8. Complications and evolution of hydrocele

Left untreated Hydroceles can lead to infection of the fluid and testicular atrophy. A large hydrocele may block the testicular blood supply leading to testicular atrophy and subsequent impairment of fertility. Haemorrhage into the hydrocele can result from testicular trauma. If a communicating hydrocele does not go away on its own and is not treated, it can lead to an inguinal hernia. In this condition, part of the intestine or intestinal fat pushes through an opening (inguinal canal) in the groin area. The prognosis for congenital hydrocele is excellent. Most congenital cases resolve by the end of the first year of life. Persistent congenital hydrocele is readily corrected surgically.

Self-assessment 8.1

- 1) Define hydrocele
- 2) What are the signs and symptoms of hydrocele?
- 3) Differentiate communicating and non-communicating hydrocele.
- 4) How is trans-illumination test done?

8.2. Description of Testicular torsion

Learning Activity 8.2

A 15 year-old male was admitted to the Emergency Department of a tertiary Hospital presenting with a sudden and continuous pain in the left testicle. The pain was progressive, radiated to the abdomen and left inguinal area, it was accompanied with nausea and vomiting of more than 12 h since its onset. On physical examination the left testicle was found to be larger in volume to the right one, was painful, local temperature had risen and there was a negative Prehn sign (exacerbation of pain upon elevation of the testicle on raising the affected testicle). There was also an absence of the cremasteric reflex which is an indicative of testicular torsion. Doppler ultrasound showed changes suggestive of testicular torsion. Emergency surgery was performed on the day of admission to correct this problem. This showed findings of a necrotic left testicle with a 360° rotation of the spermatic cord for which a left orchiectomy was performed. The pathology study reported hemorrhagic testicular infarction. There were no complications during recovery and the patient was discharged the day after surgery.

Questions related to the case study

- 1) Identify the biographic data of the patient from the case study above.
- 2) List the signs and symptoms presented by patient on his arrival to the Emergency Department.
- 3) What are the findings identified by physician on physical examination?
- 4) What is the surgical diagnosis of this patient found on Doppler ultrasound?
- 5) How was this surgical diagnosis corrected?

8.2.1. Definition of Testicular Torsion

Testicular torsion involves a twisting of the spermatic cord that supplies blood to the testes and epididymis. It is most commonly seen in males younger than age 20.

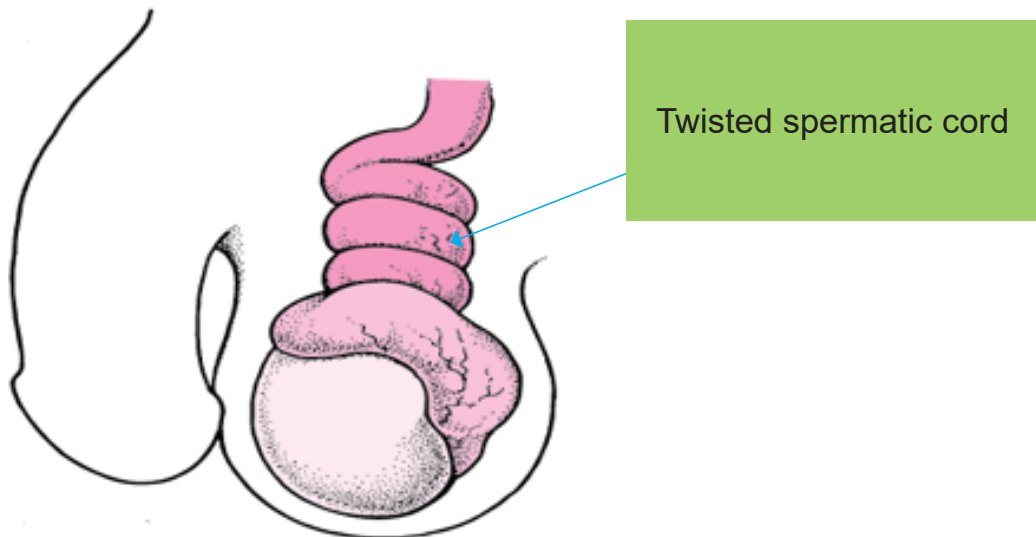


Fig 8.7 : Testicular torsion with twisted spermatic cord.

8.2.2. Causes and pathophysiology of Testicular Torsion

Testicular torsion can occur spontaneously, as a result of trauma, or as a result of an anatomic abnormality. As the testicle twists around the spermatic cord, venous blood flow is cut off, leading to venous congestion and ischemia of the testicle.

The testicle becomes tender, swollen, and possibly erythematous. As the testicle further twists, the arterial blood supply is cut off which leads to further testicular ischemia and eventually necrosis. In most individuals, the testicle rotates between 90-180 degrees and compromised blood flow. Complete torsion is rare and quickly decreases the viability of the testes. The correction is possible if the torsion is less than 8 hours but rare if more than 24 hours have elapsed.

8.2.3. Signs and symptoms of Testicular Torsion

Signs and symptoms of testicular torsion include:

Unilateral scrotal pain: The pain may be constant or intermittent, but not positional.

Associated symptoms: Nausea and vomiting, abdominal pain and inguinal pain.

Scrotal swelling and erythematous.

The testicle may be in an abnormal or transverse lie and maybe in a high position.

Absence of cremasteric reflex (Stroking of the skin causes the cremaster muscle to contract and pull up testicle toward the inguinal canal) but it is not reliable in patients less than one year. In absence of cremasteric reflex, the stroke of skin will not allow the pulling up of testicle towards inguinal canal.

The following chart summarizes the signs and symptoms of testicular torsion

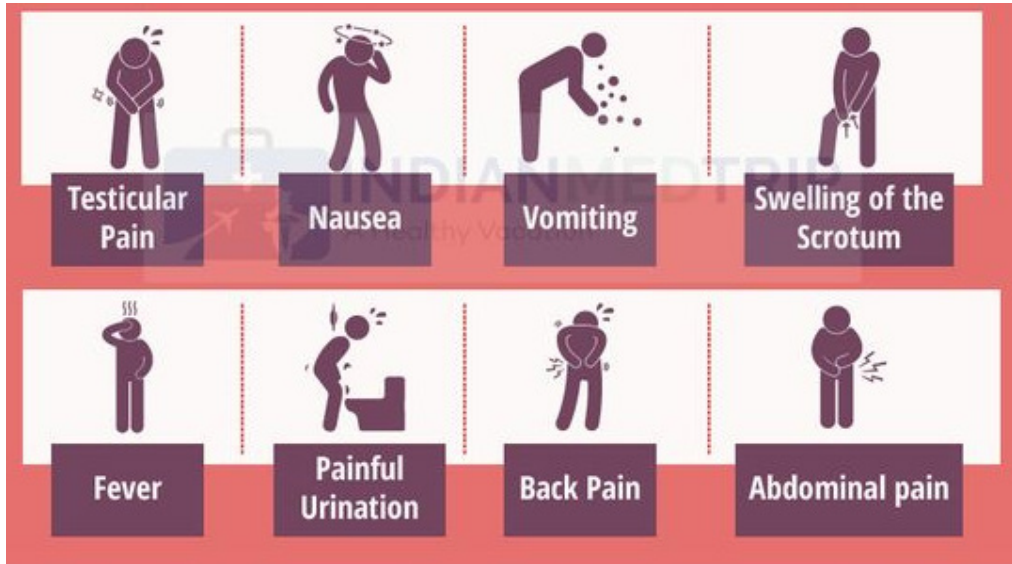


Figure 8.8 : Presence of Cremasteric reflex test

8.2.4. Diagnosis of Testicular Torsion

To diagnose testicular torsion, Doppler ultrasound is typically performed to assess blood flow within the testicle. Decreased or absent blood flow confirms the diagnosis. MRI and CT scan may also be performed. Although surgical exploration is invasive, it remains the gold standard in the diagnosis of testicular torsion.

8.2.5. Treatment plan of Testicular Torsion

Manual detorsion

Manual detorsion was first described in 1893 to reverse ischemia and provide instantaneous pain relief. This procedure may limit testicular infarction while preparations are being made for surgical exploration. The procedure is done by rotating the affected testicle at 180 degrees in clockwise direction. The procedure may need to be repeated 2–4 times, as torsion can involve rotations of 180–720 degrees. Manual detorsion should be guided by instantaneous resolution of pain and re-establishment of blood.

Surgical Exploration

Torsion constitutes a surgical emergency because, if the blood supply to the affected testicle is not restored within 4 to 6 hours, ischemia to the testis will occur, leading to necrosis and the possible need for removal. Unless the torsion resolves spontaneously, surgery to untwist the cord and restore the blood supply must be performed immediately.

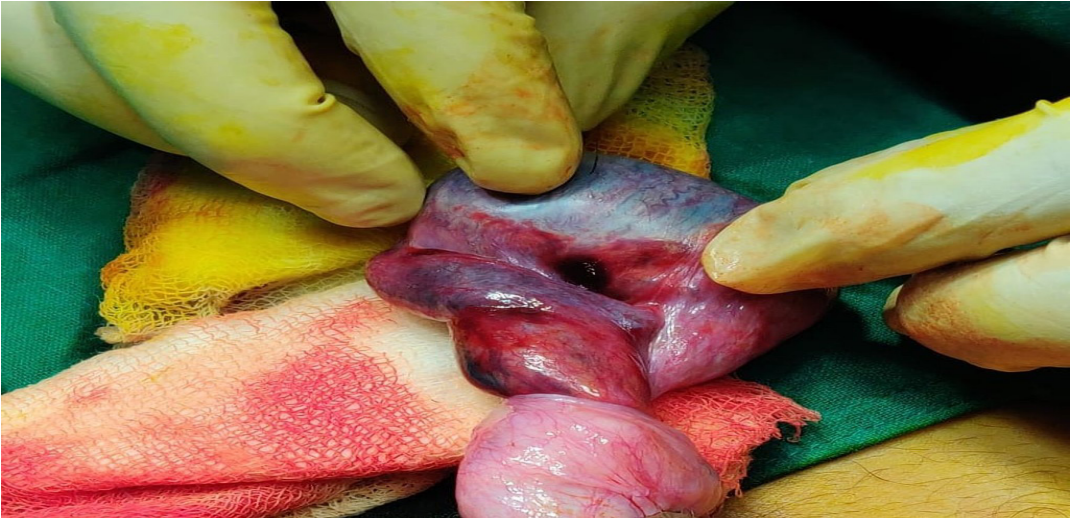

Figure 8.9: Surgical exploration of testicular torsion

8.2.6. Complications and evolution of Testicular Torsion

The common complications of testicular torsion include the following:

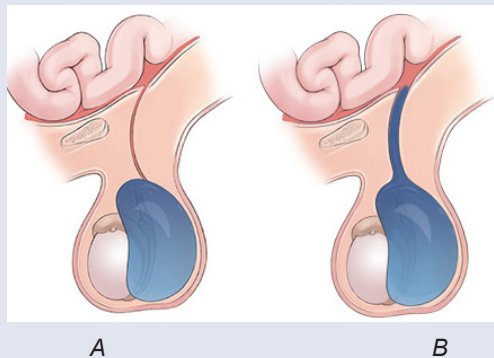
- Loss of testis
- Infection
- Infertility
- Loss or diminished exocrine and endocrine function in men

Evolution of testicular torsion

Since many years ago there has been a markable improvement in the recovery of the testes following torsion. However, poor results still occur especially in African Americans, young patients, and those who lack health insurance. Better outcome is obtained if the surgery is done within 8 hours. The outcomes of testicular torsion depend on when the patient presents to the hospital and how quickly the diagnosis is made and treatment is undertaken. Delays in diagnosis and treatment always lead to testicular atrophy. About 20-40% of cases of testicular torsion result in an orchiectomy. The risk of losing a testis is much higher among African Americans and younger males. For those who present within the first 6 hours of symptoms, the survival rate is nearly 100% but this number quickly drops to less than 50% if the delay in seeking help is more than 12-24 hours.

End Unit assessment 8

- 1) Define testicular torsion.
- 2) State two main causes of testicular torsion.
- 3) The following are the signs and symptoms of testicular torsion EXCEPT:
 - a) Scrotal pain
 - b) Nausea and vomiting
 - c) Scrotal swelling
 - d) Presence of cremasteric reflex
- 4) The following are complications of testicular torsion EXCEPT:
 - a) Loss of testis
 - b) Infection
 - c) Infertility
 - d) Increased exocrine and endocrine function in men
- 5) Identify which one among A and B is representing communicating hydrocele and non-communicating hydrocele in the following illustrations:



- 6) What is the most common imaging study performed to diagnose a testicular torsion?
- 7) State two treatment modalities of hydrocele and testicular torsion for each.

REFERENCES

- 1) Lewis, S. L., Dirksen, S. R., Heitkemer, M. M., & Linda Bucher. (2014). *MEDICAL-SURGICAL NURSING Assessment and mManagement of clinical problems (NINTH)*. Canada: ELSEVIER MOSBY.
- 2) Williams, L. S., & Hopper, P. D. (2015). *Understanding Medical Surgical Nursing (Fifth edit)*. Philadelphia: F.A. Davis Company.
- 3) Hinkle, J. L., & Cheever, K. H. (2018). *Brunner and Suddarth's textbook of medical-surgical nursing*. Wolters kluwer india Pvt Ltd.
- 4) Winkelman, C. (2016). *Medical-surgical nursing: Patient-centered collaborative care*. Elsevier